

# Diagnostic Snapshot



## What Caused This Fluid?

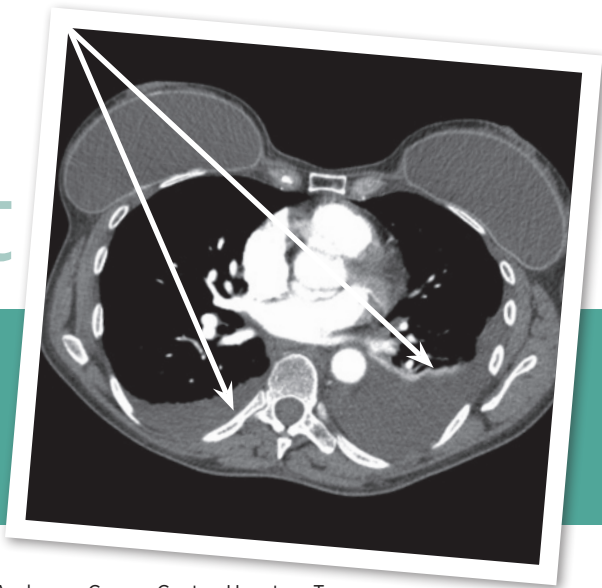


Figure 1

Courtney Robb, RN, MS, CRNFA, FNP-C

From Department of Cardiothoracic Surgery, The University of Texas MD Anderson Cancer Center, Houston, Texas

The author has no conflicts of interest to disclose.

Correspondence to: Courtney Robb, RN, MS, CRNFA, FNP-C, 1327 Lake Pointe Pkwy, Sugar Land, TX 77478.

E-mail: cmrobb@mdanderson.org

<https://doi.org/10.6004/jadpro.2018.9.5.10>

### HISTORY

Mrs. C is a 58-year-old Caucasian female with a history of bilateral pleural effusions in 2012 after strenuous exercise. In 2014, a thoracentesis that ruled out cancer with unknown cause was performed on the fluid. Her pulmonologist referred her to an oncologist for closer observation and 1 year with serial CT imaging every 3 months. The effusions did not redevelop. Her PMH includes hypothyroidism, breast augmentation, and tubal ligation. She takes levothyroxine and a multivitamin daily. She is very active and does not smoke. She has a family history of melanoma.

### CHIEF COMPLAINT

In September 2016, Mrs. C reported to her local PCP with chest tightness and a hard, dry cough that developed after strenuous exercise and would not subside. She also stated she felt something “pop” in her chest. Her local physician ordered a chest x-ray, and she was noted to have bilateral pleural effusions. Due to this finding, a CT angiogram of the chest with contrast was ordered, revealing bilateral pleural effusion with a moderate amount on the left and a small amount on the right. The angiogram did not show pulmonary emboli. There was no parenchymal consolidation or pulmonary mass. There was no evidence of intrathoracic lymphadenopathy (Figure 1). She denied fever, hemoptysis, night

sweats, chills, fatigue, or dizziness. She reported feeling slightly short of breath with exertion.

### PHYSICAL AND DIAGNOSTIC STUDIES

Mrs. C’s vital signs were stable, with a pulse oximetry of 100%. Mrs. C was well-nourished and demonstrated no fatigue and no distress. There was no palpable lymphadenopathy of the neck or supraclavicular region. Her breathing was unlabored with no signs of dyspnea. Her breath sounds were clear bilaterally on auscultation, except they were slightly diminished in the left lower lobe. There was dullness to percussion in the left lower lung. There were no wheezes, rhonchi, or crackles. On auscultation of the heart, there were no murmurs or gallops. Upon examination of her abdomen, there were no palpable masses, no guarding or tenderness, and normal bowel sounds in all four quadrants. There was no cyanosis or clubbing of the nail beds, and she had good capillary refill. There was no edema in her extremities. A PET, thoracentesis of the left lung, and lymphangiography were ordered for further evaluation. Laboratory studies, CBC with differential, CMP, and coagulation studies were performed and returned normal. Thoracentesis showed triglyceride level of 220 mg/dL of milky fluid. The study was negative for malignant cells.

© 2018 Harborside™

J Adv Pract Oncol 2018;9(5):549–551

DIFFERENTIAL  
DIAGNOSIS



### WHAT IS THE MOST LIKELY DIAGNOSIS?

A

Malignant pleural disease

B

Idiopathic chylothorax

C

Pulmonary embolism

SEE BACK FOR ANSWER



## CORRECT ANSWER B

**Idiopathic Chylothorax.** A chylothorax is the presence of the lymphatic fluid chyle in the pleural space. Chylothorax makes up about 2% of all pleural effusions in adults, and in 15% of those cases, no known cause is identified, therefore classifying them as spontaneous and idiopathic (Bender, Murthy, & Chamberlain, 2016). Chyle is secreted by intestinal cells that are transported through the thoracic duct and can accumulate in the pleural space due to leakage or obstruction of the thoracic duct or one of its major branches (Nataprawira, Rosmayudi, & Effendy, 2004). Chylothorax is a rare occurrence and a serious and potential life-threatening event if not treated accordingly.

There are two types of chylothorax: spontaneous and traumatic. Traumatic chylothoraces are caused by trauma or surgery. Spontaneous chylothorax can develop due to infection, neoplasm, superior vena cava thrombosis, cirrhosis, or for an unknown cause. In more rare cases, it has been shown to occur after strenuous exercise or valsalva maneuver. It can also present at any age, including in neonates (Bender et al., 2016).

Clinical manifestations of a chylothorax are related to the presence of fluid accumulation in the thoracic cavity. The differentiation among diagnoses of malignancy, parapneumonic effusion, or chylothorax occurs with evaluation of the pleural fluid with thoracentesis. Upon gross examination of the fluid, chyle will present as a chylous milky fluid, as seen with Mrs. C. However, it can also appear this way in a pseudochylothorax. A pseudochylothorax is a pleural effusion that is frequently associated with long-standing inflammatory disorders such as rheumatoid arthritis and tuberculosis. It is different from a chylothorax at the microscopic level (Chong, Chauhan, Di Nino, Brien, & Casserly, 2012). The pleural fluid undergoes lipid electrophoresis with microscopic and chemical evaluation. A pseudochylothorax will present with cholesterol greater than 250 mg/dL and triglycerides less than 110 mg/dL. With a chylothorax, triglyceride levels are greater than 110 mg/dL and chylomicrons are present (Bender et al., 2016). If the test is positive for triglycerides greater than 110 mg/dL, there is a less than 1% chance it is not a chylothorax, thus supporting the diagnosis with high specificity. If the fluid shows

less than 50 mg/dL triglyceride level, it is associated with a less than 5% change of being a chylous fluid, helping to rule out a chylothorax with a high degree of sensitivity (Bender et al., 2016).

## EXPLANATION OF INCORRECT ANSWERS

**Malignant Pleural Disease.** In 25% of cases, pleural effusions are caused by malignant disease (Sato, 2006). Pleural effusions are common in patients with cancer; about half of patients with cancer develop pleural effusions. Pleural effusions are especially common in Hodgkin lymphoma, with an incidence of up to 60% (Hunter, Dhakal, Voci, Goldstein, & Constine, 2014). There is up to a 20% incidence of bilateral pleural effusions seen in patients with non-Hodgkin lymphoma, most often at presentation (Hunter et al., 2014). Patients with malignant pleural effusion can present with unilateral or bilateral pleural effusions. The number 1 cause of pleural effusion in a study with 3,077 patients was cancer. Of those 3,077 patients, the most common primary tumors with malignant pleural effusion were lung (37%) and breast (16%) tumors. However, the presentation was typically unilateral (Porcel, Esquerda, Vives, & Bielsa, 2014). In another study of 264 patients, 17% of the pleural effusions were lung cancer, 10% were metastatic tumors, and 9% were mesothelioma. Overall, malignant effusions account for approximately 20% to 25% of all effusions. Therefore, when a person presents with bilateral pleural effusion, malignant cause should be ruled out (Tingquist & Steliga, 2018).

**Pulmonary Embolism.** Pulmonary embolism (PE) is the fourth leading cause of pleural effusion, and the possibility of PE should be evaluated for all patients with undiagnosed pleural effusion. The most common cause of pleuritic chest pain and pleural effusion in patients younger than 40 years old is PE. Pleural effusions can develop due to PE depending on the size, number, and location of thrombosis. Pleural effusions that develop due to PE typically occupy less than one-third of the hemithorax (Light, 2001).

## MANAGEMENT

Treatment of a chylothorax may be conservative or surgical. The conservative measure aims at re-

ducing chyle production through diet control and reducing symptoms by draining the chylous fluid from the thorax (Bender et al., 2016). Reduction in fat intake with a nonfat diet may allow for spontaneous closure of the lymphatic vessels. The closure is typically completed within a week's time or less if the patient adheres well to the diet. In patients with potential malnutrition issues, consulting a nutritionist will be important for close monitoring (Sriram, Meguid, & Meguid, 2016). More invasive interventions target the cause and either directly close the site of the leak through surgery or embolize the lymphatic vessels percutaneously (Itkin, 2016).

There is also new research evaluating pharmacotherapy treatments for chylothorax. Octreotide, a somatostatin analog, has two modes of action to help stop a chyle leak. It acts on the somatostatin receptors of the lymph ductal endothelial cells, causing smooth muscle contraction of the lymph duct to decrease leakage. It also prevents intestinal fat absorption by hindering hormone secretion from the pancreas and gastrointestinal tract, thus reducing the quantity of flowing lymph fluid. This can be administered intravenously and monitored for its response (Tabata et al., 2016).

## OUTCOME

Mrs. C underwent percutaneous image-guided lymphangiogram with possible thoracic duct embolization by interventional radiology. The lymphangiogram was successful, with lipiodol injected via the bilateral inguinal and right pelvic lymphatic system. Slow-flow lymphatics without any large active thoracic duct leak were noted.

On final CT, lipiodol was visualized at the thoracic duct confluence within the left subclavian vein. It was determined at that time, the lymphangiogram could be considered therapeutic and was attributed to mild inflammatory effects of lipiodol, and thoracic duct embolization was not needed. Mrs. C tolerated the procedure

well and was discharged home the same day. She returned in 3 months with a repeat chest CT showing no signs of pleural effusions; they had resolved. She also reported feeling well with resolution of her symptoms. ●

## References

- Bender, B., Murthy, V., & Chamberlain, R. S. (2016). The changing management of chylothorax in the modern era. *European Journal of Cardio-Thoracic Surgery*, 49(1), 18–24. <https://doi.org/10.1093/ejcts/ezv041>
- Chong, S. G., Chauhan, Z., Di Nino, E., Brien, A. O., & Casserly, B. P. (2012). Effusion under the microscope. *Monaldi Archives for Chest Disease*, 77(1), 32–34.
- Hunter, B. D., Dhakal, S., Voci, S., Goldstein, N. P. N., & Costine, L. S. (2014). Pleural effusions in patients with Hodgkin Lymphoma: Clinical predictors and associations with outcome. *Leukemia and Lymphoma*, 55(8), 1822–1826. <https://doi.org/10.3109/10428194.2013.836599>
- Itkin, M. (2016). Interventional treatment of pulmonary lymphatic anomalies. *Techniques in Vascular and Interventional Radiology*, 19(4), 299–304. <http://dx.doi.org/10.1053/j.tvir.2016.10.005>
- Light, R. W. (2001). Pleural effusion due to pulmonary emboli. *Current Opinion Pulmonary Medicine*, 7(4), 198–201. Retrieved from <https://www.ncbi.nlm.nih.gov/pubmed/11470974>
- Nataprawira, H. M., Rosmayudi, O., & Effendy, S. (2004). Recurrent idiopathic chylothorax. *Paediatrica Indonesia*, 44(6), 253–258. <https://doi.org/10.14238/pi44.6.2004.253-8>
- Porcel, J. M., Esquerda, A., Vives, M., & Bielsa, S. (2014). Etiology of pleural effusions: Analysis of more than 3,000 consecutive thoracenteses. *Archivos de Bronconeumologia*, 50(5), 161–165. <https://doi.org/10.1016/j.arbres.2013.11.007>
- Sato, T. (2006). Differential diagnosis of pleural effusions. *Japan Medical Association Journal*, 49(9), 315–319. Retrieved from [http://www.med.or.jp/english/pdf/2006\\_09+/315\\_319.pdf](http://www.med.or.jp/english/pdf/2006_09+/315_319.pdf)
- Sriram, K., Meguid, R. A., & Meguid, M. M. (2016). Nutritional support in adults with chyle leaks. *Nutrition*, 32(2), 281–286. <http://dx.doi.org/10.1016/j.nut.2015.08.002>
- Tabata, H., Ojima, T., Nakamori, M., Nakamura, M., Katsuda, M., Hayata, K.,...Yamaue, H. (2016). Successful treatment of chylothorax after esophagectomy using octreotide and etilefrine. *Esophagus: Official Journal of the Japan Esophageal Society*, 13(3), 306–310. <https://doi.org/10.1007/s10388-016-0526-8>
- Tingquist, N. D., & Steliga, M. A. (2018). Diagnosis and management of pleural metastasis and malignant effusions in breast cancer. *The Breast*, 5, 934–941. <http://doi.org/10.1016/B978-0-323-35955-9.00072-6>