

# Diagnostic Snapshot



## Acute Edema in the Oncology Patient

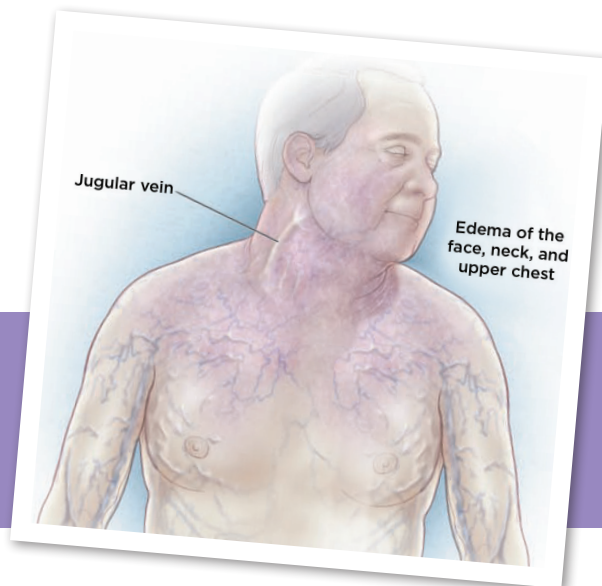


Figure 1. Reused with permission from Wilson, Detterbeck, & Yahalom (2007).

Alexandra Trudeau, BSN, BS, RN, CNOR, Danielle Bean, BSN, RN, Donna Fleming, MSN, RN, FNP-C, Glaiza Boado, BSN, RN, Natalia Samuels, MSN, RN, and Reshmi Kurup, BS, RN

From Texas Woman's University—College of Nursing, Houston, Texas  
The authors have no conflicts of interest to disclose.

Correspondence to: Alexandra Trudeau, BSN, BS, RN, CNOR, 2719 Glenn Lakes Lane, Missouri City, TX 77459. Email: atrudeau@twu.edu  
<https://doi.org/10.6004/jadpro.2018.9.6.10>

### HISTORY

A 54-year-old African American male with a recent diagnosis of acute myeloid leukemia status post chemotherapy 2 days presented to the emergency room with dull substernal chest pain, dyspnea, bilateral blurred vision, a nonproductive cough, and a headache described as a full-pressure sensation with a pain score of 8 out of 10. He was admitted to the intensive care unit (ICU) with the diagnosis of hypertensive crisis with angina. Cardiovascular risk factors included smoking for 20 years, hypertension, hyperlipidemia, and end-stage renal disease. His chemotherapy regimen consisted of anthracycline and cytarabine. Home medications included amlodipine, atorvastatin, calcitriol, voriconazole, ferrous sulfate, hydrocodone, megestrol acetate, metoprolol tartrate, ascorbic acid, ondansetron orally disintegrating tablets, trimethoprim-sulfamethox-

azole, and daily filgrastim injection for chemotherapy-induced neutropenia. He received one unit of packed red blood cells and one unit of apheresis platelets 2 days prior to admission.

### PHYSICAL EXAM

In the ICU, vitals displayed a heart rate of 113 beats per minute (tachycardia), blood pressure 210/108 mm Hg, temperature 99.8°F, and respiratory rate 26, with an oxygen saturation of 93% on room air. The patient was lethargic and unable to follow simple commands. Lung sounds were diminished in the right middle lobe and bilateral lower lobes. He had an acute onset of edema in the face, neck, and upper extremities, with facial plethora. His chest and jugular veins were visibly distended. No edema in the lower extremities was noted. The remainder of his physical exam was unremarkable.



WHICH OF THE FOLLOWING IS THE MOST LIKELY DIAGNOSIS FOR THIS PATIENT?

- A Mediastinitis
- B Superior vena cava syndrome
- C Nephrotic syndrome

## CORRECT ANSWER: B

**Superior Vena Cava Syndrome.** The superior vena cava (SVC) is responsible for circulation from the head, neck, upper extremities, and torso into the right atrium. The blood flow through the SVC can become obstructed in an oncology patient, most often from mediastinal malignancies associated with small cell bronchogenic carcinoma, non-Hodgkin lymphoma, and metastatic tumors, to name a few (Seligson & Surowiec, 2017). Patients receiving hemodialysis, long-term antibiotics, or chemotherapy are also at risk for SVC syndrome due to possible thrombus formation on an indwelling catheter (Seligson & Surowiec, 2017). Stenosis of the SVC causes a rapid rise in collateral vessel pressure. It can take several weeks for the body to accommodate to this pressure increase (Danjoux et al., 2015). Therefore, like this man, patients with SVC syndrome acutely present with dyspnea, a sensation of fullness in the head, distention of the neck and chest veins, and edema of the face, eyelids, and upper extremities (Danjoux et al., 2015).

## EXPLANATION OF INCORRECT ANSWERS

**Mediastinitis.** Mediastinitis is a potentially fatal bacterial infection of the mediastinum with multiple etiologies. An acute presentation is most commonly the result of an esophageal rupture or a complication post thoracic surgery (Choe et al., 2014). On rare occasion, the infection arises from the oral and pharyngeal cavity (Choe et al., 2014). In fibrosing mediastinitis, vital structures may become compressed due to collagen formation from the inflammatory response (Schade & Mirani, 2013). General symptoms include dyspnea, chest pain, cough, and hemoptysis (Schade & Mirani, 2013). Patients can also present with tachycardia, fever, and palpable crepitus over the chest wall (Choe et al., 2014). Mediastinitis was ruled out for this patient due to his nonproductive cough without hemoptysis, denial of any recent oral or pharyngeal infections, and no recent thoracic surgery.

**Nephrotic Syndrome.** This syndrome is the result of increased glomerular permeability causing proteinuria, hypoalbuminemia, and hyperlipidemia (Al-Azzawi, Obi, Safi, & Song, 2016). New-onset edema in the proximal lower extremities is

a characteristic sign of nephrotic syndrome (Kodner, 2016). Other signs and symptoms include exertional dyspnea, periorbital edema, pleural effusion, hypertension, and ascites not associated with heart failure or liver disease (Kodner, 2016). Venous thromboembolism is often reported as a complication of this condition (Al-Azzawi, Obi, Safi, & Song, 2016). Nephrotic syndrome was ruled out due to no evidence of lower extremity edema, ascites, or past medical history of heart failure or liver disease.

## WORKUP

Yu, Wilson, and Detterbeck (2008) proposed a classification system and algorithm for the management of SVC syndrome. It starts with obtaining a radiograph and a computed tomography (CT) scan with contrast of the chest to determine whether the obstruction is from a solid mass or a thrombus. It can also provide the size and relative position of the obstruction. A tissue biopsy for staging can be obtained through multiple invasive procedures, such as a bronchoscopy, mediastinoscopy, or CT-guided needle biopsy. Further diagnostics may include a magnetic resonance angiogram (MRA), and/or a positron emission tomography (PET) scan. The MRA differentiates between the superior and inferior vena cava and measures the diameter and degree of SVC stenosis. These provide a solid basis for planning endovascular treatment (Lepper et al., 2011). Alternatively, a PET scan is more sensitive in revealing metastasis and lymph node involvement. Endobronchial ultrasound-guided transbronchial needle aspiration has shown a high yield and is safe for patients with SVC syndrome caused by a mediastinal mass (Feng & Pennell, 2012). Contrast venography studies provide a map of the blood vessels supplying the mediastinum and help in determining the patency of vessels.

## MANAGEMENT

Treating the underlying cause is the goal to proper management in patients with SVC syndrome. Historically, an aortic aneurysm caused by tertiary syphilis was the origin of SVC syndrome, in which antibiotics were considered as first-line therapy (Straka et al., 2016). However, neoplastic masses and thrombi associated with intravascular devices have now emerged as the most common causes.

To determine the course of action, venographic classification is done to ascertain whether or not a case is emergent. It also determines the rate of tumor progression and the level of obstruction to the surrounding structures (Straka et al., 2016). For instance, conditions such as laryngeal and cerebral edema are considered medical emergencies that merit immediate stenting and empiric treatment of the root cause prior to obtaining a biopsy. If a thrombus is the culprit, anticoagulation therapy has shown an 88% success rate when initiated within the first 5 days of formation (Straka et al., 2016). For malignancies, radiation can be used alone or in combination with either steroids or chemotherapy. This helps to shrink the tumor and provides palliative support (Straka et al., 2016). Furthermore, advances in technology have allowed patients treated with stents for SVC syndrome to report immediate symptom relief as soon as 0 to 72 hours post procedure (Straka et al., 2016). When combined with chemotherapy and/or radiation, it has also been shown that they generally live longer (Straka et al., 2016).

## OUTCOME

Superior vena cava syndrome is a condition that can be managed with supportive care and early intervention. Recognizing the cardinal signs of upper body venous congestion can guide the practitioner to the proper diagnosis and course of treatment. For the patient in this case, imaging revealed that his acute symptoms were related to a mediastinal mass compressing the SVC. As stated, malignant masses are now one of the most common causes of SVC syndrome. Ideally, further workup would have involved a biopsy and staging to determine the best course of action to relieve his symptoms of SVC syndrome. However, the gentleman's condition rapidly declined. He was intubated for airway protection, and then a sudden drop in blood pressure required multiple pressors. His ICU stay was further complicated with sepsis, likely due to his immunocompromised state status post chemotherapy and antibiotic treatments. Further-

more, he had acute chronic renal failure requiring continuous renal replacement therapy. Had his condition not been so unstable, this patient could have possibly benefited from stent placement and chemoradiation with steroids for palliative support. Unfortunately, he expired due to his hemodynamic instability and profound sepsis. ●

## References

- Al-Azzawi, H. F., Obi, O. C., Safi, J., & Song, M. (2016). Nephrotic syndrome-induced thromboembolism in adults. *International Journal of Critical Illness and Injury Science*, 6(2), 85–88. <http://doi.org/10.4103/2229-5151.183019>
- Choe, I. S., Kim, Y. S., Lee, T. H., Kim, S. M., Song, K. H., Koo, H. S.,...Choi, I. S. (2014). Acute mediastinitis arising from pancreatic mediastinal fistula in recurrent pancreatitis. *World Journal of Gastroenterology*, 20(40), 14997–15000. <http://doi.org/10.3748/wjg.v20.i40.14997>
- Danjoux, C., Lechner, B., Pulenzas, N., Tsao, M., Barnes, E., & Chow, E. (2015). Superior vena cava syndrome. *Journal of Pain Management*, 8(4), 283–287.
- Feng, Y., & Pennel, N. A. (2012). Superior vena cava syndrome in lung cancer. *Lung Cancer Management*, 1(4), 309–315. <https://doi.org/10.2217/lmt.12.38>
- Kodner, C. (2016). Diagnosis and management of nephrotic syndrome in adults. *American Family Physician*, 93(6), 479–485. Retrieved from <https://pdfs.semanticscholar.org/0ff1/9f168833dfa3f3efc553e3bf3b3db34b110b.pdf>
- Lepper, P. M., Ott, S. R., Hoppe, H., Schumann, C., Stammberger, U., Bugalho, A., & Hamacher, J. (2011). Superior vena cava syndrome in thoracic malignancies. *Respiratory Care*, 56(5), 653–665. <https://doi.org/10.4187/respcare.00947>
- Schade, M. A., & Mirani, N. M. (2013). Fibrosing mediastinitis: An unusual cause of pulmonary symptoms. *Journal of General Internal Medicine*, 28(12), 1677–1681. <http://doi.org/10.1007/s11606-013-2528-8>
- Seligson, M. T., & Surowiec, S. M. (2017). Superior vena cava syndrome. *Stat Pearls [Internet]*. Retrieved from <https://www.ncbi.nlm.nih.gov/books/NBK441981/>
- Straka, C., Ying, J., Kong, F., Willey, C. D., Kaminski, J., & Kim, D. W. (2016). Review of evolving etiologies, implications and treatment strategies for the superior vena cava syndrome. *SpringerPlus*, 5(229). <http://dx.doi.org/10.1186/s40064-016-1900-7>
- Wilson, L. D., Detterbeck, F. C., & Yahalom, J. (2007). Superior vena cava syndrome with malignant causes. *New England Journal of Medicine*, 356, 1862–1869. <https://doi.org/10.1056/NEJMc067190>
- Yu, J. B., Wilson, L. D., & Detterbeck, F. C. (2008). Superior vena cava syndrome—a proposed classification system and algorithm for management. *Journal of Thoracic Oncology*, 3(8), 811. <https://doi.org/10.1097/JTO.0b013e3181804791>