

# Infrequent Offenders: Neuroendocrine Tumors and Cancers of the Appendix, Gallbladder, and Bile Duct

PRESENTED BY KRISTEN O'HAGAN, ANP-BC, MS, AOCNP®

From Memorial Sloan Kettering Cancer Center, New York, New York

Presenter's disclosure of conflicts of interest is found at the end of this article.

<https://doi.org/10.6004/jadpro.2021.12.3.20>

© 2021 Harborside™

## Abstract

During JADPRO Live Virtual 2020, Kristen O'Hagan, ANP-BC, MS, AOCNP®, provided an overview of rare gastrointestinal tumors, their presentation, and current treatment algorithms. Ms. O'Hagan also discussed the advanced practitioner's role in managing these diseases.

**D**uring JADPRO Live Virtual 2020, Kristen O'Hagan, ANP-BC, MS, AOCNP®, of Memorial Sloan Kettering Cancer Center, described the presentation, diagnosis, and treatment algorithms of rare gastrointestinal tumors, including neuroendocrine tumors and cancers of the appendix, gallbladder, and bile duct.

## NEUROENDOCRINE TUMORS

Neuroendocrine tumors are a rare but diverse group of cancers that arise out of endocrine cells and can occur anywhere in the gastrointestinal tract and the bronchopulmonary system. The incidence of neuroendocrine tumors is approximately 7 per 100,000 people, and between 40% and 50% of cases present with distant metastases (Dasari et al., 2017). Ms. O'Hagan's session focused on neuroendocrine tumors of the GI tract.

Treatment and patient outcome depends on the location of the primary cancer, tumor grade, and burden of disease. Well-differentiated neuroendocrine tumors are classified into three groups: low grade, intermediate grade, and high grade. Poorly differentiated neuroendocrine tumors are characterized by metastatic disease at presentation and clinical behavior similar to that of small-cell carcinoma of the lung. Neuroendocrine tumors are also categorized by their functionality, which is based on the presence of symptoms resulting from excess secretion of hormones by the tumor.

## Assessment/Staging

As Ms. O'Hagan explained, a full extent of disease staging is important because prognosis is related to disease burden. Reliable imaging is critical in determining the extent of the disease, said Ms. O'Hagan.

Surgery is the only curative treatment. Workup for these tumors includes serum and urine tests, along with imaging.

Chromagranin A (serum marker) is an appropriate tumor marker for patients with an established diagnosis in order to assess disease progression, response to therapy, or recurrence after surgical resection. The level is affected by other factors and is not considered diagnostic. 5-HIAA is a measure of serotonin byproduct in the urine and is thought to play a major role in the development of carcinoid syndrome.

Dotatate PET scan is the newest modality and the most useful test to establish disease burden in these patients. It is superior to CT scan and octreotide scans with regards to sensitivity in detecting presence of disease. For patients with liver metastases, MRI of the liver is used with Eovist as contrast is used to capture the volume of liver disease.

### **Treatment of Resectable Disease**

If all disease is amenable to surgical resection, said Ms. O'Hagan, then surgery is potentially curative. However, even if all disease cannot be removed, several studies have shown that debulking up to 70% of the tumor is associated with a survival benefit (Morgan et al., 2018). When surgery is not an option, liver-directed therapy with hepatic artery embolization has demonstrated symptom control and progression-free survival in carcinoid syndrome.

### **Treatment of Unresectable Disease**

For well-differentiated neuroendocrine tumors that are not amenable to surgery or in cases where not all disease is removed, treatment is generally either observation or somatostatin analogs (octreotide or lanreotide). Somatostatin analogs bind to somatostatin receptors that are expressed by the majority of neuroendocrine tumors. These drugs help control symptoms and decrease time to progression.

For patients who have progressed on somatostatin analogs, two drugs have been approved: everolimus (Afinitor) and lutetium (or Lu-177; Lutathera). Everolimus, a targeted agent, was approved in 2016 based on data from the RADIANT-4 trial, which showed a median survival of

11 months in patients receiving the drug vs. 3 to 9 months on placebo (Yao et al., 2016).

Lu-177 was approved in 2018 and has a completely different delivery system. The drug is a radiolabeled somatostatin analog used as a peptide receptor radionuclide therapy and is given intravenously every 3 months. Between 74% and 80% of patients see disease response with Lu-177 (Saravana-Bawan et al., 2019).

The COMPETE trial, a phase III, prospective, randomized study that will compare everolimus and Lu-177 head-to-head, is currently enrolling in 47 international locations.

## **CANCER OF THE APPENDIX**

Approximately 1% of appendectomy specimens are cancers, and these account for 0.5% to 1% of all intestinal neoplasms (Unver et al., 2018). There are two types of cancer that occur in the appendix: epithelial neoplasms and neuroendocrine tumors (Figure 1). The latter are the most common and typically affect young adults but can occur in children (age 5 to 19) as well.

Prognosis is related to tumor grade and differentiation as well as tumor size, but overall survival is approximately 95%. In tumors less than 2 cm, there is a 12% chance of nodal metastasis, while tumors greater than 2 cm have a 43% chance of nodal metastasis.

For tumors greater than 2 cm or incomplete resection, staging involves triple-phase CT or MRI of the abdomen and pelvis. Dotatate PET is reserved for patients with suspected metastatic disease.

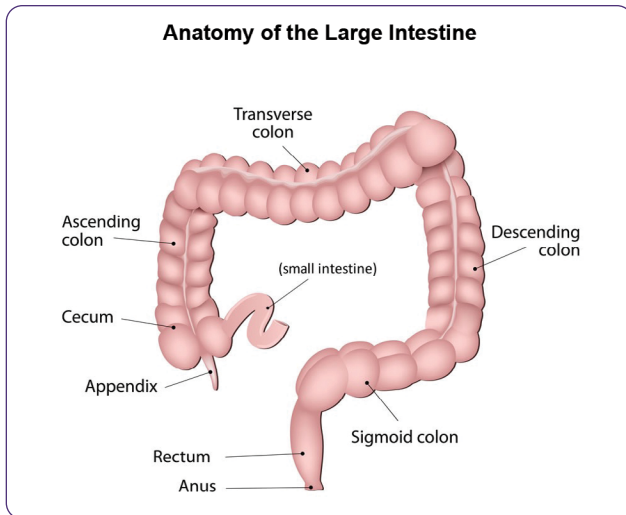
For patients with tumors less than 2 cm, treatment is a simple appendectomy. For tumors larger than 2 cm, treatment is a right hemicolectomy with lymph node dissection (Pape et al., 2012).

"Follow-up care is debated in the literature," said Ms. O'Hagan. "Patients who have a low risk of recurrence may check their chromogranin A levels annually to make sure they're not rising."

## **GALLBLADDER CANCER**

With approximately 5,000 cases per year, gallbladder cancer is the most common cancer of the biliary tract in the world (Figure 2).

"Overall, it's a devastating diagnosis," said Ms. O'Hagan. "The mean overall survival is 6 months, and the 5-year survival rate is only 5%."



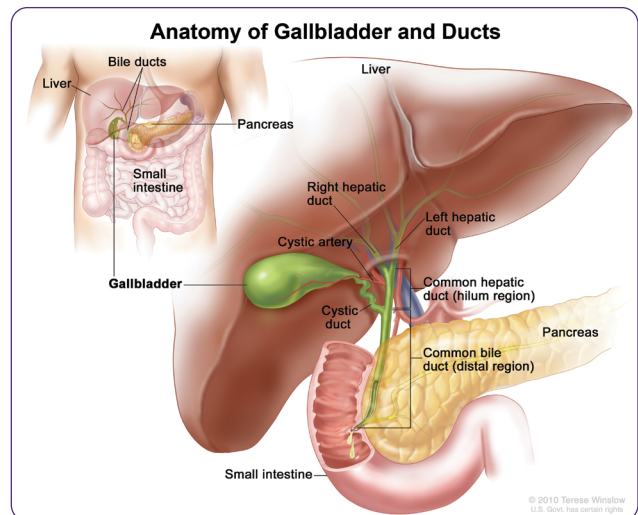
**Figure 1.** Cancer of the appendix. There are two types of cancers that occur in the appendix: neuroendocrine neoplasms and epithelial neoplasms.

Between 60% and 70% of the cases are found incidentally at the time of cholecystectomy. Due to the complexity of the disease, outcomes are better at National Comprehensive Cancer Network-designated care centers, said Ms. O'Hagan, who noted that surgery is the only curative treatment, and the extent of surgery is based on the tumor stage. The reoperation involves a partial hepatectomy, removal of the gallbladder, the bile duct, and the portal lymph nodes, and a recreation of the bile duct.

"Because patients can have complications from the radical reoperations, they need to be in centers where there are experienced surgeons and the teams recognize the complications early on and intervene," said Ms. O'Hagan.

A single-agent capecitabine given for 6 months has been approved as adjuvant therapy for patients with resected gallbladder cancer and has demonstrated some statistical benefit. Advanced disease is not curable, however, and survival is less than 6 months. No targeted agents have been approved at this time.

"Given the anatomy, jaundice is often difficult to address in these patients and requires a skilled interventional radiology and gastrointestinal team working in tandem," said Ms. O'Hagan. "Gastric outlet obstruction can also be an issue with the duodenum getting stuck onto the tumor." Advanced practitioners should advocate for early initiation of supportive care in patients with advanced disease.



**Figure 2.** Anatomy of gallbladder and ducts. © 2010 Terese Winslow LLC, U.S. Govt. has certain rights.

## CHOLANGIOCARCINOMA

With approximately 3,000 cases in the United States each year, bile duct cancer comprises approximately 3% of all gastrointestinal malignancies (Miller et al., 2020). As Ms. O'Hagan explained, presentation, symptoms, and treatment are dependent on where in the bile ducts the cancer occurs.

Risk factors include primary sclerosing cholangitis, choledochal cysts (cystic liver disorders), parasitic infections (particularly in Asia), older age, and male sex.

"Treatment of cholangiocarcinoma takes a village," said Ms. O'Hagan. "The interdisciplinary team includes hepatobiliary surgeons, medical oncologists, gastroenterologists with advanced endoscopic retrograde cholangiopancreatography skills, and interventional radiologists with exquisite skill who have to puncture bile ducts that can be smaller than spaghetti and work with the gastrointestinal team to facilitate drainage."

Given the enormous challenges faced by patients with this disease, advanced practitioners also play a critical role on the multidisciplinary team.

"All along the way, there are advanced practitioners and nursing staff who are very attuned to this patient population and accustomed to working together for the best outcome," Ms. O'Hagan added.

For patients with surgical resectable disease, despite the small size of the tumors, and depending on where in the bile duct they are,

Ms. O'Hagan explained that these can be “huge” operations. The goal of surgery is curative. The surgery can involve removing the right two thirds of the liver along with removing and reconstructing the bile duct, or if the tumor is in the distal bile duct, the patient undergoes a Whipple procedure. Nevertheless, approximately two thirds of patients will still experience disease recurrence.

In the adjuvant setting, capecitabine was approved based on the results of the BILCAP study, which showed a statistical advantage among patients who received a single-agent capecitabine for 6 months (Adeva et al., 2019).

Although surgery is the preferential treatment, less than 40% of patients make it to surgery, said Ms. O'Hagan, who noted that most patients have unresectable disease at presentation. Jaundice and cholangitis are known challenges in caring for patients with cholangiocarcinoma. These challenges present in the preoperative and postoperative setting, and in nonoperative patients. Cholangitis is a medical emergency. Prompt recognition of the infection, administration of antibiotics and biliary drainage or stent changes are critical.

Although there are no approved targeted therapies, there are many in development, including several targeting *FGFR2* mutations. ●

## Disclosure

Ms. O'Hagan had no conflicts of interest to disclose.

## References

- Adeva, J., Sangro, B., Salati, M., Edeline, J., La Casta, A., Bittoni, A.,...Valle, J. W. (2019). Medical treatment for cholangiocarcinoma. *Liver International*, 39(S1), 123–142. <https://doi.org/10.1111/liv.14100>
- Dasari, A., Shen, C., Halperin, D., Zhao, B., Zhou, S., Xu, Y.,... Yao, J. C. (2017). Trends in the incidence, prevalence, and survival outcomes in patients with neuroendocrine tumors in the United States. *JAMA Oncology*, 3(10), 1335–1342. <https://doi.org/10.1001/jamaoncol.2017.0589>
- Miller, K. D., Fidler-Benaoudia, M., Keegan, T. H., Hipp, H. S., Jemal, A., & Siegel, R. L. (2020). Cancer statistics for adolescents and young adults, 2020. *CA: A Cancer Journal for Clinicians*, 70(6), 443–459. <https://doi.org/10.3322/caac.21637>
- Morgan, R. E., Pommier, S. J., & Pommier, R. F. (2018). Expanded criteria for debulking of liver metastasis also apply to pancreatic neuroendocrine tumors. *Surgery*, 163(1), 218–225. <https://doi.org/10.1016/j.surg.2017.05.030>
- Pape, U.-F., Perren, A., Niederle, B., Gross, D., Gress, T., Costa, F.,...Grossman, A. (2012). ENETS Consensus Guidelines for the Management of Patients with Neuroendocrine Neoplasms from the Jejunum-Ileum and the Appendix Including Goblet Cell Carcinomas. *Neuroendocrinology*, 95(2), 135–156. <https://doi.org/10.1159/000335629>
- Saravana-Bawan, B., Bajwa, A., Paterson, J., McEwan, A., & McMullen, T. (2019). Efficacy of 177Lu peptide receptor radionuclide therapy for the treatment of neuroendocrine tumors: A meta-analysis. *Clinical Nuclear Medicine*, 44(9), 719–727. <https://doi.org/10.1097/rlu.0000000000002646>
- Unver, N., Coban, G., Arıcı, D. S., Buyukpinarbasılı, N., Guçin, Z., Malya, F. Ü.,...Topalan, K. (2018). Unusual histopathological findings in appendectomy specimens: A retrospective analysis of 2047 cases. *International Journal of Surgical Pathology*, 27(2), 142–146. <https://doi.org/10.1177/1066896918784650>
- Yao, J. C., Fazio, N., Singh, S., Buzzoni, R., Carnaghi, C., Wolin, E.,...Strosberg, J. (2016). Everolimus for the treatment of advanced, non-functional neuroendocrine tumours of the lung or gastrointestinal tract (RADIANT-4): A randomised, placebo-controlled, phase 3 study. *The Lancet*, 387(10022), 968–977. [https://doi.org/10.1016/s0140-6736\(15\)00817-x](https://doi.org/10.1016/s0140-6736(15)00817-x)