Immunoglobulin Light-Chain Amyloidosis: Clinical Presentations and Diagnostic Approach

YI L. HWA, DNP,[1] TERESA FOGAREN, MSN, AGNP-C,[2] ALLISON SAMS, AGPCNP-BC,[3] DOUGLAS V. FALLER, MD, PhD,[4] DAWN M. STULL, PharmD, BCOP,[5] SARA THUENEMANN, RN, MSN, DHSc,[6] and LISA MENDELSON, MSN, AGPCNP-BC[7]

From [1]Division of Hematology, Mayo Clinic, Rochester, Minnesota; [2]Division of Hematology-Oncology, Tufts Medical Center, Boston, Massachusetts; [3]Division of Hematology-Oncology, Outpatient Multiple Myeloma Service, Memorial Sloan-Kettering Cancer Center, New York City, New York; [4]Millennium Pharmaceuticals, Inc., Cambridge, Massachusetts, a wholly owned subsidiary of Takeda Pharmaceutical Company Limited; [5]Global Medical Affairs Oncology, Millennium Pharmaceuticals, Inc., Cambridge, Massachusetts, a wholly owned subsidiary of Takeda Pharmaceutical Company Limited; [6]Global Medical Affairs Oncology, Millennium Pharmaceuticals, Inc., Cambridge, Massachusetts, a wholly owned subsidiary of Takeda Pharmaceutical Company Limited; [7]Amyloidosis Center, Boston University School of Medicine, Boston, Massachusetts.

Authors' disclosures of conflicts of interest are found at the end of this article.

Correspondence to: Yi L. Hwa, DNP, Division of Hematology, Mayo Clinic, 200 First Street SW, Rochester, MN 55905. E-mail: hwa.yi@mayo.edu

https://doi.org/10.6004/jadpro.2019.10.5.5

© 2019 Harborside™

Abstract

Systemic immunoglobulin light-chain (AL) amyloidosis is a rare disorder arising from a plasma cell clone that produces misfolded immunoglobulin light chains, which are deposited in various tissues and organs as amyloid fibrils. Signs and symptoms are typically vague and overlap with those arising from other common diseases; consequently, diagnosis of AL amyloidosis is challenging for clinicians. Substantial delays between onset of symptoms and diagnosis are common, and result in poorer outcomes, particularly in patients with cardiac AL amyloidosis and others who develop advanced organ dysfunction. With the need to identify AL amyloidosis as early as possible, it is important for health-care practitioners, including advanced practice clinicians and nurses, to be aware of the hallmark presenting signs and symptoms, as well as the latest practice for evaluation and diagnosis. Increased awareness of signs and symptoms associated with AL amyloidosis, particularly relating to the most frequently involved organs, the heart and kidneys, represents an opportunity for achieving earlier diagnosis. Here we review these issues in AL amyloidosis, summarize the key presenting symptoms that clinicians need to be alert to, and discuss the latest diagnostic tests, with the aim of expediting patient identification and diagnosis with the goal of improving patient outcomes.

Systemic immunoglobulin light-chain (AL) amyloidosis is caused by plasma cell clones in the bone marrow (median 7%–10% marrow infiltration) that produce insoluble, misfolded immunoglobulin light chain proteins, which are deposited in various tissues and organs as amyloid fibrils leading to progressive organ dysfunction (Gertz, 2016; Grogan, Dispenzieri, & Gertz, 2017; Kastritis & Dimopoulos, 2016). This systemic disease is a rare disorder, with an estimated annual incidence of 6 to 10 per million person-years in the

J Adv Pract Oncol 2019;10(5):470–481

United Kingdom and United States (Banypersad, Moon, Whelan, Hawkins, & Wechalekar, 2012; Comenzo, 2007a, 2007b; Merlini & Palladini, 2008). The actual number of patients with this disorder may be higher due to underdiagnosis, with a recent real-world epidemiological study estimating an incidence of up to 14 per million person-years in the United States (Quock, Yan, Chang, Guthrie, & Broder, 2018). AL amyloidosis is a disease that occurs in adults and is predominantly seen in the sixth decade of life (median age at diagnosis being estimated as 60–63 years); however, amyloidosis has been diagnosed in patients as young as 40 and is more prevalent in male patients (Abeykoon et al., 2017; Comenzo, 2007a, 2007b; Merlini & Palladini, 2008). There are approximately 30 different types of amyloidogenic proteins that may cause systemic or localized disease (Sipe et al., 2014), and AL amyloidosis is one of the most common forms of systemic disease (Palladini & Merlini, 2016). Signs and symptoms of AL amyloidosis are dependent on the involved organs and severity of organ damage. Initial symptoms are nonspecific, vary widely, and often overlap with those arising from other common diseases (Gertz, 2016; Grogan et al., 2017; Lousada, Comenzo, Landau, Guthrie, & Merlini, 2015; Palladini & Merlini, 2016). Consequently, the diagnosis of this rare condition represents a challenge for clinicians.

Data from a patient experience survey by the Amyloidosis Research Consortium, which included 533 patients with amyloidosis (72% AL), showed that 37% of patients did not receive their definitive diagnosis of amyloidosis until ≥ 1 year from the initial onset of symptoms, with 32% requiring visits to ≥ 5 physicians before establishing the diagnosis of amyloidosis, and 34% of patients were diagnosed by hematology/oncology specialists (Lousada et al., 2015). Other reports have also noted substantial delays in the diagnosis of AL amyloidosis (McCausland et al., 2018; Muchtar et al., 2016) associated with the challenges of nonspecific symptoms and misdiagnosis. In a longitudinal, noninterventional study of community-based patients with AL amyloidosis, patients reported an average of 3 years from symptom onset to diagnosis (McCausland et al., 2018).

These delays in diagnosis have a significant impact on patients as treatment outcomes are poorer in patients who experience a delay in diagnosis compared with those who achieve early diagnosis (Grogan et al., 2017). This review highlights the need for early recognition of clinical presentations and diagnostic approach for systemic AL amyloidosis specifically, summarizing the key presenting symptoms that clinicians need to be alert to, and discussion of the latest diagnostic tests, with the aim of expediting symptom identification and diagnosis.

THE IMPORTANCE OF EARLY DIAGNOSIS OF AL AMYLOIDOSIS

Establishing an early diagnosis of AL amyloidosis is important because it enables treatment to be started early in the disease course, with the aim of reducing the burden of the free light-chain (FLC) producing plasma cell clone, thereby preventing further organ damage (Merlini & Palladini, 2012). A high percentage of bone marrow plasma cells and baseline FLC burden at diagnosis predict poor survival, and a reduction in FLC with therapy is associated with improved outcomes (Dispenzieri et al., 2006; Kourelis et al., 2013; Kumar et al., 2010; Lachmann et al., 2003). The spectrum and severity of organ involvement also have a great impact on prognosis and survival (Kyle, Greipp, & O'Fallon, 1986). Although autologous peripheral blood stem cell transplantation (ASCT) is an effective therapy for AL amyloidosis, with a 10-year survival rate of 43% (Sidiqi et al., 2018), the majority of patients are ineligible for this aggressive treatment due to significant organ dysfunction or comorbidities.

Frequency of Common Organ Involvement

Multisystem organ involvement is the hallmark of AL amyloidosis. In a single-center series, Merlini and Palladini reported that 68% of patients had more than one organ involved at diagnosis (Merlini & Palladini, 2008). The criteria defining organ involvement in AL amyloidosis, in addition to evidence of amyloid deposits from organ or alternate-site biopsy, are summarized in Table 1 (Gertz et al., 2005; National Comprehensive Cancer Network, 2018).

The most commonly involved organs are the kidney and the heart, either individually or together (Grogan et al., 2017). In various reports of patient series or clinical studies, 48% to 80% of patients had renal involvement (Jun et al., 2013; Kyle et al., 1997; Merlini & Palladini, 2008; Michael et

Table 1. Criteria Defining Organ Involvement in AL Amyloidosis

Organ	Criteria
Kidney	24-hour urine protein > 0.5 g/day, predominantly albumin
Heart	Mean left ventricular wall thickness (septum and posterior wall) > 12 mm in the absence of hypertension or other possible causes of left ventricular hypertrophy; low voltage on 12-lead electrocardiography; elevated (> 332 ng/L) concentration of NT-proBNP in the absence of renal failure or atrial fibrillation (BNP concentration may also be used)
Liver	Total liver span > 15 cm in the absence of heart failure or alkaline phosphatase > 1.5 times the institutional upper limit of normal
Nervous system	Peripheral: clinical evidence of symmetric lower extremity sensorimotor peripheral neuropathy Autonomic: gastric-emptying disorder, pseudo-obstruction, voiding dysfunction not related to direct organ infiltration
Gastrointestinal tract	Direct biopsy verification with symptoms
Lung	Direct biopsy verification with symptoms; interstitial radiographic pattern
Soft tissue	Tongue enlargement (macroglossia); arthropathy (shoulder-pad sign); claudication, presumed vascular amyloid; skin involvement; enlarged lymph nodes; carpal tunnel syndrome; myopathy by biopsy or pseudohypertropy

Note. AL = systematic immunoglobin light-chain; NT-proBNP = N-terminal pro-brain natriuretic peptide; BNP = B-type natriuretic peptide.
Adapted with permission from Gertz, MA, et al. *Am J Hematol*. 79 (2005) 319-28. © John Wiley and Sons.
Adapted with permission from the NCCN Clinical Practice Guidelines in Oncology (NCCN Guidelines®) for Systemic Light Chain Amyloidosis V.1.2019. © 2018 National Comprehensive Cancer Network, Inc. All rights reserved. The NCCN Guidelines® and illustrations herein may not be reproduced in any form for any purpose without the express written permission of NCCN. To view the most recent and complete version of the NCCN Guidelines, go online to NCCN.org. The NCCN Guidelines are a work in progress that may be refined as often as new significant data becomes available.

al., 2010; Skinner et al., 2004; Vesole et al., 2006), and 21% to 70% had cardiac involvement (Jun et al., 2013; Kyle et al., 1997; Merlini & Palladini, 2008; Michael et al., 2010; Skinner et al., 2004; Vesole et al., 2006). Recent data suggested that 80% of patients were estimated to have dominant cardiac amyloid, and two thirds had dominant renal amyloid at diagnosis (Milani, Merlini, & Palladini, 2018). In patients with cardiac AL amyloidosis, advanced cardiac dysfunction is estimated to result in up to 30% of patients dying within 90 days of diagnosis (Grogan et al., 2017; Palladini & Merlini, 2016), and AL amyloidosis patients with high FLC burden are likely to have more severe cardiac involvement (Kumar et al., 2010).

Other commonly involved organs are liver and nerve systems. Approximately 16% to 22% of AL amyloidosis patients have liver involvement, manifesting as hepatomegaly and elevation of alkaline phosphatase at diagnosis (Gertz, 2018; Merlini & Palladini, 2012; Merlini, Wechalekar, & Palladini, 2013), although in the presence of heart failure, the clinical differentiation of amyloid infiltration from venous congestion may not be possible (Guidelines Working Group of UK Myeloma Forum & British Committee for Standards in Haematology British Society for Haematology, 2004). Nervous system involvement (peripheral or autonomic) is present in 14% to 20% of patients, with 20% presenting with peripheral neuropathy (Benson & Kincaid, 2007; Merlini & Palladini, 2012).

PRESENTING SIGNS AND SYMPTOMS

The most critical step to early and correct diagnosis is to suspect AL amyloidosis on the basis of the clinical manifestations (Kastritis & Dimopoulos, 2016). A formal diagnosis of AL amyloidosis is not usually made until signs or symptoms referable to a particular organ appear (Falk, Comenzo, & Skinner, 1997; Grogan et al., 2017; Guidelines Working Group of UK Myeloma Forum & British Committee for Standards in Haematology British Society for Haematology, 2004; National Comprehensive Cancer Network, 2018). It is therefore important for advanced practice clinicians and nurses to be aware of the multiple signs and symptoms that could give rise to clinical suspicion of AL amyloidosis. Increased awareness of the potential for

certain signs and symptoms to be associated with AL amyloidosis, particularly relating to the most frequently involved organs (heart and kidneys), represents an opportunity for achieving earlier diagnosis (Lousada et al., 2015).

The initial presentation of AL amyloidosis can be subtle and nonspecific, and usually depends on the organ(s) involved (Comenzo et al., 2012; Falk et al., 1997; Muchtar et al., 2017b; National Comprehensive Cancer Network, 2018), such as shortness of breath, weakness, orthopnea, polyneuropathy, swelling of the ankles and legs, and macroglossia (Jun et al., 2013; Lousada et al., 2015; Merlini et al., 2013); in a retrospective analysis of Korean patients with AL amyloidosis, pitting edema was the most common initial presentation, occurring in 26% of patients (Jun et al., 2013).

Cardiac involvement is common in AL amyloidosis, with cardiac amyloidosis a diagnostic consideration in patients presenting with nondilated or restrictive cardiomyopathy with preserved ejection fraction (Carrizales-Sepulveda, Ordaz-Farias, Vera-Pineda, Benavides-Gonzalez, & Flores-Ramirez, 2017; Flodrova et al., 2018). Other signs include low-voltage QRS and pseudo infarct patterns on electrocardiogram, orthostatic hypotension associated with low cardiac output, left ventricular hypertrophy with increased interventricular septal diameter > 12 mm, and/or diastolic dysfunction, and late gadolinium enhancement on cardiac MRI. Other symptoms include shortness of breath, edema, atypical chest pain from small vessel disease, ascites, and syncope (Carrizales-Sepulveda et al., 2017; Guidelines Working Group of UK Myeloma Forum & British Committee for Standards in Haematology British Society for Haematology, 2004; Merlini & Palladini, 2012; Wechalekar et al., 2013).

Renal involvement is also common in AL amyloidosis and a diagnosis should be considered in patients presenting with nephrotic syndrome with or without renal insufficiency (Guidelines Working Group of UK Myeloma Forum & British Committee for Standards in Haematology British Society for Haematology, 2004). Symptoms potentially associated with AL amyloidosis with renal involvement can include ankle swelling, dizziness due to orthostatic hypotension, frothy urine from proteinuria, peripheral edema, mild renal impairment, and hypercholesterolaemia in patients with nephrotic syndrome (Guidelines Working Group of UK Myeloma Forum & British Committee for Standards in Haematology British Society for Haematology, 2004). It is important to note that nephrotic range proteinuria can occur with normal renal function.

Peripheral neuropathy could be a sign of peripheral nervous system involvement in AL amyloidosis (Benson & Kincaid, 2007). Specific symptoms associated with sensory neuropathy may include paresthesia, numbness, and muscle weakness due to co-occurring myopathy. Additionally, postural hypotension, impotence, dry mouth and eyes, and disturbed gastrointestinal (GI) motility may be associated with autonomic neuropathy in AL amyloidosis patients with nervous system involvement (Guidelines Working Group of UK Myeloma Forum & British Committee for Standards in Haematology British Society for Haematology, 2004; Merlini & Palladini, 2012; Muchtar et al., 2017b).

Specific GI involvement may be associated with a range of presenting symptoms including weight loss, nausea, diarrhea, disturbed GI motility, and GI bleeding (Cowan et al., 2013; Guidelines Working Group of UK Myeloma Forum & British Committee for Standards in Haematology British Society for Haematology, 2004; Iida, Yamano, & Nakase, 2018). AL amyloidosis with hepatic involvement—another commonly involved organ site—should be considered for patients presenting with unexplained hepatomegaly with normal imaging or isolated elevated alkaline phosphatase in the absence of transaminitis (Guidelines Working Group of UK Myeloma Forum & British Committee for Standards in Haematology British Society for Haematology, 2004). Macroglossia, which is highly indicative of AL amyloidosis, submandibular and cervical gland enlargement, and carpal tunnel syndrome are indicative of soft tissue involvement (Merlini & Palladini, 2012).

Rare Presentations

Various other symptoms, reflecting the involvement of other organ systems, may be present; indeed, any organ other than the brain can be involved in AL amyloidosis (Guidelines Working Group of UK Myeloma Forum & British Committee for Standards in Haematology British Society

for Haematology, 2004). Approximately 15% of patients have soft tissue involvement at presentation (Milani et al., 2018). Less common signs and symptoms that could indicate AL amyloidosis include: skin and soft-tissue thickening, painful seronegative arthropathy, bone involvement, hoarse voice, hypoadrenalism, hypothyroidism, lymphadenopathy, and pulmonary infiltration (Guidelines Working Group of UK Myeloma Forum & British Committee for Standards in Haematology British Society for Haematology, 2004). Myopathy is a rare presentation, often misdiagnosed, and serum creatine kinase levels have been shown to be an unreliable biomarker (Muchtar et al., 2016). While uncommon, ocular manifestations of amyloidosis have been reported, as a result of involvement of various organ systems. The deposition of amyloid fibrils has been documented in the conjunctiva, temporal artery, extraocular muscle, trabecular meshwork, and cranial nerves (Reynolds et al., 2017). Reports of temporal artery biopsies performed to confirm a diagnosis of suspected giant cell arteritis (Ghinai et al., 2017; Kanaan, Lorenzi, Thampy, Pandit, & Dayan, 2017) and to determine the cause of bilateral sequential optic neuropathy (Kanaan et al., 2017) have revealed amyloid deposits confirming a diagnosis of AL amyloidosis in these patients.

DIAGNOSTIC STRATEGIES TO CONFIRM AL AMYLOIDOSIS

A number of diagnostic workup algorithms are available in order to guide clinicians through the process of establishing a clear diagnosis of AL amyloidosis (Gertz, 2018; National Comprehensive Cancer Network, 2018; Palladini & Merlini, 2016); a recently published algorithm by Gertz is reproduced in Figure 1. If AL amyloidosis is suspected based on the presenting signs and symptoms, patients undergo an initial workup to detect the presence of amyloid deposits and to evaluate organ function (Table 2). First, an assessment for the underlying plasma cell dyscrasia is performed by serum and urine protein electrophoresis and immunofixation, and the immunoglobulin FLC assay for κ and λ immunoglobulin light chains (Merlini & Palladini, 2008; Palladini et al., 2017). If the screening tests are positive, subcutaneous fat aspiration and bone marrow biopsy are then carried out to determine the presence of amyloid by characteristic Congo red staining (Dispenzieri et al., 2015; Fernandez de Larrea et al., 2015; Milani et al., 2018). Other histological staining such as Thioflavin stains may be used; however, Congo red staining is generally the most accepted and considered the standard for detection of amyloid (Dispenzieri et al., 2015). Bone marrow evaluation may determine the presence of plasma cell dyscrasia, the percentage of plasma cells, and plasma cell genetics by fluorescence in situ hybridization (Gertz, 2018). The salivary gland is used as an alternative site for biopsy if the abdominal fat aspirate is negative, with a sensitivity of 58% (Foli et al., 2011). If fat aspirate and bone marrow are both negative but clinical suspicion for amyloid remains high, then a tissue biopsy of the organs thought to be involved (heart, liver, kidney, nerve, etc.) is collected (Gertz, 2018) and stained with Congo red. Although all biopsies carry a risk of bleeding, liver biopsies should be carried out with caution due to the increased risk of hemorrhage (Palladini & Merlini, 2016).

Once the diagnosis of amyloidosis has been made, the type of amyloidosis that is present must be determined. When stained using Congo red, the amyloid deposits produce a pathognomonic red-green birefringence under cross-polarized light microscopy (Comenzo, 2007a; Falk et al., 1997; Merlini & Bellotti, 2003). However, Congo red staining and fluorescent birefringence alone do not distinguish AL amyloidogenic protein from other forms of amyloidosis such as transthyretin (TTR), hereditary apolipoprotein AI, or acquired amyloid A (AA) amyloidosis due to chronic inflammation; typing of the amyloid deposits is therefore mandatory to confirm a diagnosis of AL amyloidosis. The most commonly available techniques to classify amyloid deposits are IHC and IF; however, these tests can be misleading when classifying amyloid deposits (Gertz, 2018). A more reliable amyloid typing technique is the mass spectrometry–based proteomic analysis (Gertz, 2018). Although more expensive and available to a limited number of specialized medical centers, mass spectrometry is the current gold standard for determining the type of amyloidosis (Gertz, 2018). Early referral of the patient to a center of excellence where accurate amyloid typing can be done is crucial to confirm the diagnosis.

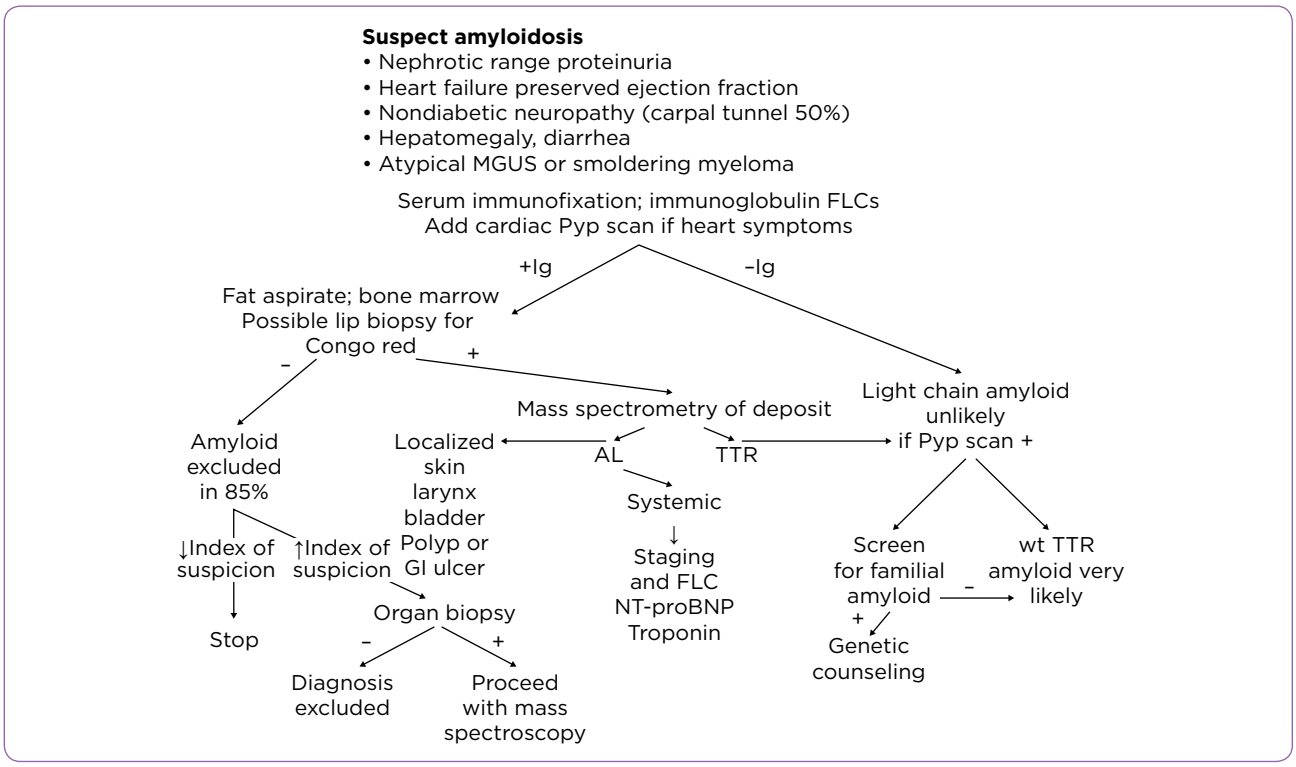

Figure 1. Diagnostic algorithm for AL amyloidosis. Reproduced with permission from Gertz MA. *Blood Cancer J.* 8 (2018) 44. http://creativecommons.org/licenses/by/4.0/.
AL = amyloid light-chain; MGUS = monoclonal gammopathy of undetermined significance; FLC = free light-chain; Pyp = technetium-99m stannous pyrophosphate; TTR = transthyretin-related; GI = gastrointestinal; Ig = immunoglobulin; wt = wild type; NT-proBNP = N-terminal pro-brain natriuretic peptide.

DEVELOPMENTS IN TECHNIQUES TO ASSESS ORGAN INVOLVEMENT

Once the diagnosis and typing of AL amyloidosis are established, additional evaluations may be conducted to assess the manifestation and extent of organ involvement. Patients with renal involvement commonly present with increased proteinuria (mainly albuminuria), evolving into nephrotic syndrome and progressing into renal failure if untreated (Palladini & Merlini, 2016). Twenty-four-hour urinary protein loss and estimated glomerular filtration rate (eGFR) are the standard tests to evaluate renal involvement (Palladini & Merlini, 2016). The assessment of proteinuria by 24 hour urine collection can be used to assess organ response and monitor organ progression. The common clinical features of liver involvement can be assessed using liver function tests to detect abnormal liver enzymes, especially elevated alkaline phosphatase, and liver imaging using CT, ultrasound, or MRI to evaluate hepatomegaly (Palladini & Merlini, 2016). Suspected GI involvement may warrant endoscopic evaluation with biopsy to help confirm a diagnosis by using Congo red staining to detect the presence of amyloid (Iida et al., 2018). Cardiac involvement of amyloidosis can be assessed through electrical disturbances or lowered voltage in limb leads on electrocardiography, while echocardiographic evidence of increasing wall thickness and abnormality of longitudinal ventricular strain pattern may also highlight AL amyloidosis with cardiac involvement (Carrizales-Sepulveda et al., 2017; Grogan et al., 2017). Furthermore, specific biomarkers are used to establish and stage cardiac AL amyloidosis, including N-terminal pro-brain natriuretic peptide (NT-proBNP) and cardiac troponin T (cTnT). Cardiac MRI with gadolinium is now available to evaluate cardiac amyloidosis, particularly when echocardiogram findings are inconclusive (Grogan et al., 2017). Cardiac MRI can provide specific imaging features to detect cardiac involvement by

Table 2. Initial Diagnostic Workup of AL Amyloidosis

Step	Test	Aim
Clinical and amyloid-related assessment	Orthostatic vital signs	Suspecting diagnosis of AL amyloidosis
	History and physical	
	Chest x-ray	
	Skeletal survey	
Laboratory evaluation (screening tests)	CBC differential and platelet count	Assessing effect of medication
	PT, PTT, factor X (if indicated)	Assessing coagulation deficiency
	Serum quantitative immunoglobulins, SPEP and SIFE	Characterizing presence of plasma cell dyscrasia and κ and λ immunoglobulin light chains
	24-hour urinary total protein, UPEP and UIFE	
	Serum FLC assay	
	Serum BUN/creatinine, electrolytes, albumin and calcium	Assessing renal function
	Creatinine clearance	
	Serum uric acid	
	NT-proBNP[a], troponin T	Assessing cardiac function
	Alkaline phosphatase, liver enzymes, bilirubin	Assessing hepatic function
Pathologic evaluation	Bone marrow aspirate and biopsy with immunohistochemical staining for κ and λ and Congo red staining for amyloid	Detecting the presence of amyloid deposit
	Plasma cell FISH	
	Abdominal fat pad aspirate, and involved organ biopsy as clinically indicated if both fat pad and bone marrow biopsy are negative (alternative sites include rectal or minor salivary gland biopsy)	
	Mass spectrometry	Accurate tissue typing

Note. AL = systematic immunoglobin light-chain; CBC = complete blood cell count; PT = prothrombin time; PTT = partial thromboplastin time; SPEP = serum protein electrophoresis; SIFE = serum immunofixation electrophoresis; UPEP = urine protein electrophoresis; UIFE = urine immunofixation electrophoresis; FLC = free-light chain; BUN = blood urea nitrogen; NT-proBNP = N-terminal pro-brain natriuretic peptide; FISH = fluorescence in-situ hybridization.
[a]If NT-ProBNP is not available, BNP can be performed.
Adapted with permission from the NCCN Clinical Practice Guidelines in Oncology (NCCN Guidelines®) for Systemic Light Chain Amyloidosis V.1.2019. © 2018 National Comprehensive Cancer Network, Inc. All rights reserved. The NCCN Guidelines® and illustrations herein may not be reproduced in any form for any purpose without the express written permission of NCCN. To view the most recent and complete version of the NCCN Guidelines, go online to NCCN.org. The NCCN Guidelines are a work in progress that may be refined as often as new significant data becomes available.

amyloidosis; however, it does not distinguish the light chain amyloidosis from non-AL type amyloidoses (Grogan et al., 2017). Cardiac scintigraphy (Gertz, 2018; Palladini & Merlini, 2016) with technetium-99m (^{99m}Tc) stannous pyrophosphate (PYP) or ^{99m} 3,3 diphosphono-1, 2-propanodicarboxylic acid (DPD) may be helpful to distinguish AL from transthyretin (ATTR) cardiac amyloidosis and potentially obviate the need for cardiac biopsy (Gertz, 2018; Palladini & Merlini, 2016), particularly in elderly patients with the absence of a plasma cell dyscrasia (Bokhari et al., 2013; Siddiqi & Ruberg, 2018). When a monoclonal protein is present, biopsy to detect amyloid deposit and to confirm amyloid type is required to establish an accurate diagnosis (Grogan et al., 2017).

DIFFERENTIAL DIAGNOSES

The differential diagnosis for AL amyloidosis includes systemic non-AL amyloidoses (including AA and ATTR types), localized light-chain amyloidosis, and other paraprotein-associated diseases including peripheral neuropathy and immunoglobulin deposition diseases (Guidelines Working

Group of UK Myeloma Forum & British Committee for Standards in Haematology British Society for Haematology, 2004). Among the numerous different types of systemic amyloidosis, AL comprises 78% of new cases (Palladini & Merlini, 2016). The mutated transthyretin (ATTRm) and wild-type transthyretin (ATTRwt) systemic amyloidosis are found in approximately 7% and 6% to 10% of new cases, respectively. ATTRm is hereditary and is found primarily in the peripheral and autonomic system (Palladini & Merlini, 2016), the heart, and the eye; common clinical features include heart failure and peripheral or autonomic neuropathy (Grogan et al., 2017). In ATTRwt the heart is involved in almost all cases, as well as the ligaments and tenosynovium (Palladini & Merlini, 2016); common clinical presentations include atrial fibrillation, heart failure with carpal tunnel syndrome, tendon rupture, and spinal stenosis (Grogan et al., 2017).

Distinguishing the AL and ATTR subtypes can be difficult due to the overlapping symptoms and because patients can have ATTR amyloidosis and monoclonal gammopathy of undetermined significance (MGUS; Phull et al., 2018). In some patients with ATTR, a monoclonal protein component and abnormal FLC have been identified, which are usually characteristic of AL amyloidosis (Geller et al., 2017); for such cases, biopsy to confirm the presence of amyloid and accurate typing for distinguishing the amyloid subtypes are required. While imaging with PYP or DPD can help to distinguish ATTR from AL amyloidosis, gene sequencing should be used to determine hereditary components of amyloidosis (Gertz, 2018).

Patients who are already being treated for multiple myeloma (MM) and patients with MGUS who are being monitored may also have or may develop AL amyloidosis (Grogan et al., 2017; Merlini & Palladini, 2012). Approximately 10% to 15% of patients with MM may develop primary amyloidosis and up to 38% of patients with MM have been reported to have AL amyloid deposits in the absence of readily discernible signs or symptoms (Desikan et al., 1997; Madan et al., 2010; Rajkumar, Gertz, & Kyle, 1998). Due to the clonal nature of all three conditions, patients with MM or MGUS should be assessed carefully for symptoms specific to AL amyloidosis in order to establish a diagnosis as early as possible (Merlini & Palladini, 2012). Assessment for an abnormal FLC ratio and for abnormal cardiac or renal parameters can help begin the diagnostic process prior to symptomatic manifestation of organ involvement in patients with MGUS (Merlini & Palladini, 2012); additional "red flags" have been suggested for early identification of AL amyloidosis with other organ involvement, such as alkaline phosphatase elevation, neuropathic pain, and the onset of hypotension (Merlini & Palladini, 2012). In patients with AL amyloidosis secondary to MM, specific non-myeloma symptoms require investigation; for example, one case report in the literature highlighted a female patient with MM who also presented with macroglossia and restricted tongue movement (Dawoud & Ariyaratnam, 2016). Diagnosis of AL amyloidosis was established by the identification of amyloid deposits in the oral cavity following a full oral soft-tissue examination (Dawoud & Ariyaratnam, 2016).

STAGING OF AL AMYLOIDOSIS

Following confirmation of AL amyloidosis, disease stage is determined. The survival outcome of patients with AL amyloidosis varies greatly and often depends on the severity of organ involvement, in particular cardiac dysfunction at diagnosis. Staging of AL amyloidosis at diagnosis allows prognostic stratification in order to select the optimal treatment approach in which the intensity is balanced with the patients' performance status (Milani et al., 2018). Patients with advanced cardiac disease with no treatment (Mayo stages IIIa and IIIb) had a median survival of less than 1 year (Palladini, Milani, & Merlini, 2015). Current validated staging systems are outlined in Table 3. The original Mayo Clinic 2004 prognostic staging system uses serum cTnT (< 0.035 ng/mL) and NT-proBNP (< 332 pg/mL) to stratify AL amyloidosis into three stages (Dispenzieri et al., 2004). The revised Mayo Clinic staging includes the difference between involved and uninvolved FLC (dFLC) as prognostic variables, where one point is assigned for each of dFLC ≥ 18 mg/dL, cTnT ≥ 0.025 ng/mL, or NT-proBNP ≥ 1,800 pg/mL (Kumar et al., 2012). The European staging system further added systolic blood pressure < 100 mm Hg and NT-proBNP > 8,500 pg/mL to further classify the stage III

Table 3. Staging Systems and Associated Prognostic Stage, Risk Factors, and Survival Outcomes for Patients With AL Amyloidosis

Staging systems	Prognostic variables	Stage	Number of risk factors	Median survival, months		Reference
				cTnT model	cTnI model	
Mayo Clinic 2004 AL amyloidosis staging	NT-proBNP ≥ 332 ng/L cTnT ≥ 0.035 ng/mL (or cTnI ≥ 0.1 ng/mL)	I II III	0 1 2	26.4 10.5 3.5	27.2 11.1 4.1	Dispenzieri et al., 2004
Advanced cardiac stage	Mayo 2004 AL amyloidosis stage III plus systolic blood pressure < 100 mm Hg NT-proBNP > 8,500 ng/L	III (IIIA: NT-proBNP < 8,500 ng/L; IIIB: NT-proBNP ≥ 8,500 ng/L)	0 1 2	26 6 3	IIIA: 17 IIIB: 4.6	Wechalekar et al., 2013
					5-year OS	
Mayo Clinic 2012 AL amyloidosis staging	NT-proBNP ≥ 1,800 ng/L cTnT ≥ 0.025 ng/mL dFLC ≥ 18 mg/dL	I II III IV	0 1 2 3	94.1 40.3 14 5.8	59% 42% 20% 14%	Kumar et al., 2012

Note. AL = systemic immunoglobin light-chain; NT-proBNP = N-terminal pro-brain natriuretic peptide; cTnT = cardiac troponin T; cTnI = cardiac troponin I; dFLC = difference between involved and uninvolved free-light chain; OS = overall survival.

from the original Mayo 2004 staging system into stage IIIa and IIIb (Wechalekar et al., 2013).

SENSITIVITY AND DETECTION RATES OF DIAGNOSTIC TESTS

Serum and urine immunofixation electrophoresis have been shown to detect a monoclonal component (with λ/κ ratio of 75/25) in 97% of patients, and FLC measurements have been shown to have a sensitivity of 76% (Merlini & Palladini, 2008), while other studies have demonstrated higher detection rates (up to 97%) by FLC assay in AL amyloidosis patients (Bochtler et al., 2008; Morris et al., 2007). Subcutaneous fat aspirate is the least invasive and often the first approach, offering 79% sensitivity in AL amyloidosis (Fernandez de Larrea et al., 2015). However, target organ biopsy should be pursued if clinical suspicion remains high and fat aspirate is negative, as a biopsy sample from a symptomatic organ has higher sensitivity than that from the more accessible tissues (Dispenzieri et al., 2015). Combined with bone marrow biopsy, subcutaneous fat aspirate can demonstrate AL amyloidosis in more than 85% of patients (Gertz, 2018), while other studies have demonstrated a sensitivity of 98.9% for AL amyloidosis with renal involvement through a combination of skin, fat, and rectal mucosal biopsies (Li et al., 2017), and of 84% for AL amyloidosis with cardiac involvement using abdominal fat pad fine-needle aspiration (Quarta et al., 2017). Further, a recent analysis showed that the sensitivity of abdominal fat pad excisional biopsy could be increased to almost 100% if large enough biopsies (> 700 mm^3) were used (Garcia, Collins, & Stone, 2018). It has been reported that fat aspirate is being underused for diagnosis of AL amyloidosis, and that a substantial proportion of patients could avoid a more invasive organ biopsy due to the sensitivity and utility of fat pad aspiration for recognizing the disease (Muchtar et al., 2017a).

CONCLUSIONS

Early recognition of signs and symptoms potentially associated with AL amyloidosis is the key to identification and diagnosis of the disease before substantial organ damage can occur and is thus important for improving treatment outcomes and survival. Advanced practice clinicians and oncology nurses should be aware of the common presenting signs and symptoms that could give rise to clinical suspicion of AL amyloidosis with specific organ involvement. They should also be cognizant of the subsequent needs for further diagnostic workup and, if warranted, urgent referral to a center of excellence. This would ensure an early diagnosis of AL amyloidosis when therapeutic treatments are more effective, and subsequently result in improved prognosis and quality of life of

patients. Patients with AL amyloidosis should ultimately be evaluated by a team of amyloid experts to help guide the treatment choices.

Acknowledgment

The authors would like to thank Steve Hill and Laura Webb of FireKite (an Ashfield Company, part of UDG Healthcare PLC) for medical writing assistance, which was funded by Millennium Pharmaceuticals, Inc. All editorial procedures complied with Good Publication Practice-3 (GPP3) guidelines (Battisti et al., 2015).

Disclosure

Yi L. Hwa, Teresa Fogaren, Allison Sams, and Lisa Mendelson have nothing to disclose. Douglas V. Faller, Dawn M. Stull, and Sara Thuenemann are employees of Millennium Pharmaceuticals, Inc., Cambridge, Massachusetts, a wholly owned subsidiary of Takeda Pharmaceutical Company Limited.

References

Abeykoon, J. P., Paludo, J., Dispenzieri, A., Gertz, M. A., Dingli, D., Baudi, F. K.,...Kapoor, P. (2017). Outcome of very young (≤ 40 years) patients with immunoglobulin light chain (AL) amyloidosis. *Amyloid, 24*(supp 1), 50–51. https://doi.org/10.1080/13506129.2017.1286584

Banypersad, S. M., Moon, J. C., Whelan, C., Hawkins, P. N., & Wechalekar, A. D. (2012). Updates in cardiac amyloidosis: A review. *Journal of the American Heart Association, 1*(2), e000364. https://doi.org/10.1161/JAHA.111.000364

Benson, M. D., & Kincaid, J. C. (2007). The molecular biology and clinical features of amyloid neuropathy. *Muscle and Nerve, 36*(4), 411–423. https://doi.org/10.1002/mus.20821

Battisti, W. P., Wager, E., Baltzer, L., Bridges, D., Cairns, A., Carswell, C. I.,...Yarker, Y. E. (2015). Good Publication Practice for Communicating Company-Sponsored Medical Research: GPP3. *Annals of Internal Medicine, 163*(6), 461–464. https://doi.org/10.7326/M15-0288

Bochtler, T., Hegenbart, U., Heiss, C., Benner, A., Cremer, F., Volkmann, M.,...Schonland, S. O. (2008). Evaluation of the serum-free light chain test in untreated patients with AL amyloidosis. *Haematologica, 93*(3), 459–462. https://doi.org/10.3324/haematol.11687

Bokhari, S., Castano, A., Pozniakoff, T., Deslisle, S., Latif, F., & Maurer, M. S. (2013). (99m)Tc-pyrophosphate scintigraphy for differentiating light-chain cardiac amyloidosis from the transthyretin-related familial and senile cardiac amyloidoses. *Circulation: Cardiovascular Imaging, 6*(2), 195–201. https://doi.org/10.1161/CIRCIMAGING.112.000132

Carrizales-Sepulveda, E. F., Ordaz-Farias, A., Vera-Pineda, R., Benavides-Gonzalez, M. A., & Flores-Ramirez, R. (2017). Congestive heart failure with preserved ejection fraction in a patient with light chain (AL) amyloidosis and multiple myeloma. *American Journal of Case Reports, 18*, 790–793. Retrieved from https://www.ncbi.nlm.nih.gov/pubmed/28701686

Comenzo, R. L. (2007a). Current and emerging views and treatments of systemic immunoglobulin light-chain (Al) amyloidosis. *Contributions to Nephrology, 153*, 195–210. https://doi.org/10.1159/000096768

Comenzo, R. L. (2007b). Managing systemic light-chain amyloidosis. *Journal of the National Comprehensive Cancer Network, 5*(2), 179–187. Retrieved from https://www.ncbi.nlm.nih.gov/pubmed/17335687

Comenzo, R. L., Reece, D., Palladini, G., Seldin, D., Sanchorawala, V., Landau, H.,...Merlini, G. (2012). Consensus guidelines for the conduct and reporting of clinical trials in systemic light-chain amyloidosis. *Leukemia, 26*(11), 2317–2325. https://doi.org/10.1038/leu.2012.100

Cowan, A. J., Skinner, M., Seldin, D. C., Berk, J. L., Lichtenstein, D. R., O'Hara, C. J.,...Sanchorawala, V. (2013). Amyloidosis of the gastrointestinal tract: A 13-year, single-center, referral experience. *Haematologica, 98*(1), 141–146. https://doi.org/10.3324/haematol.2012.068155

Dawoud, B. E. S., & Ariyaratnam, S. (2016). Amyloidosis presenting as macroglossia and restricted tongue movement. *Dental Update, 43*(7), 641–642, 645–647. https://doi.org/10.12968/denu.2016.43.7.641

Desikan, K. R., Dhodapkar, M. V., Hough, A., Waldron, T., Jagannath, S., Siegel, D.,...Tricot, G. (1997). Incidence and impact of light chain associated (AL) amyloidosis on the prognosis of patients with multiple myeloma treated with autologous transplantation. *Leukemia and Lymphoma, 27*(3–4), 315–319. https://doi.org/10.3109/10428199709059685

Dispenzieri, A., Buadi, F., Kumar, S. K., Reeder, C. B., Sher, T., Lacy, M. Q.,...Gertz, M. A. (2015). Treatment of immunoglobulin light chain amyloidosis: Mayo Stratification of Myeloma and Risk-Adapted Therapy (mSMART) Consensus Statement. *Mayo Clinic Proceedings, 90*(8), 1054–1081. https://doi.org/10.1016/j.mayocp.2015.06.009

Dispenzieri, A., Gertz, M. A., Kyle, R. A., Lacy, M. Q., Burritt, M. F., Therneau, T. M.,...Jaffe, A. S. (2004). Serum cardiac troponins and N-terminal pro-brain natriuretic peptide: A staging system for primary systemic amyloidosis. *Journal of Clinical Oncology, 22*(18), 3751–3757. https://doi.org/10.1200/JCO.2004.03.029

Dispenzieri, A., Lacy, M. Q., Katzmann, J. A., Rajkumar, S. V., Abraham, R. S., Hayman, S. R.,...Gertz, M. A. (2006). Absolute values of immunoglobulin free light chains are prognostic in patients with primary systemic amyloidosis undergoing peripheral blood stem cell transplantation. *Blood, 107*(8), 3378–3383. https://doi.org/10.1182/blood-2005-07-2922

Falk, R. H., Comenzo, R. L., & Skinner, M. (1997). The systemic amyloidoses. *New England Journal of Medicine, 337*(13), 898–909. https://doi.org/10.1056/NEJM199709253371306

Fernandez de Larrea, C., Verga, L., Morbini, P., Klersy, C., Lavatelli, F., Foli, A.,...Merlini, G. (2015). A practical approach to the diagnosis of systemic amyloidoses. *Blood, 125*(14), 2239–2244. https://doi.org/10.1182/blood-2014-11-609883

Flodrova, P., Flodr, P., Pika, T., Vymetal, J., Holub, D., Dzubak, P.,...Scudla, V. (2018). Cardiac amyloidosis: From clinical suspicion to morphological diagnosis. *Pathology, 50*(3), 261–268. https://doi.org/10.1016/j.pathol.2017.10.012

Foli, A., Palladini, G., Caporali, R., Verga, L., Morbini, P., Obici, L.,...Merlini, G. (2011). The role of minor salivary gland bi-

opsy in the diagnosis of systemic amyloidosis: Results of a prospective study in 62 patients. *Amyloid, 18*(suppl 1), 80–82. https://doi.org/10.3109/13506129.2011.574354029

Garcia, Y., Collins, A. B., & Stone, J. R. (2018). Abdominal fat pad excisional biopsy for the diagnosis and typing of systemic amyloidosis. *Human Pathology, 72*, 71–79. https://doi.org/10.1016/j.humpath.2017.11.001

Geller, H. I., Singh, A., Mirto, T. M., Padera, R., Mitchell, R., Laubach, J. P., & Falk, R. H. (2017). Prevalence of monoclonal gammopathy in wild-type transthyretin amyloidosis. *Mayo Clinic Proceedings, 92*(12), 1800–1805. https://doi.org/10.1016/j.mayocp.2017.09.016

Gertz, M. A. (2016). Immunoglobulin light chain amyloidosis: 2016 update on diagnosis, prognosis, and treatment. *American Journal of Hematology, 91*(9), 947–956. https://doi.org/10.1002/ajh.24433

Gertz, M. A. (2018). Immunoglobulin light chain amyloidosis diagnosis and treatment algorithm 2018. *Blood Cancer Journal, 8*(5), 44. https://doi.org/10.1038/s41408-018-0080-9

Gertz, M. A., Comenzo, R., Falk, R. H., Fermand, J. P., Hazenberg, B. P., Hawkins, P. N.,...Grateau, G. (2005). Definition of organ involvement and treatment response in immunoglobulin light chain amyloidosis (AL): A consensus opinion from the 10th International Symposium on Amyloid and Amyloidosis, Tours, France, 18–22 April 2004. *American Journal of Hematology, 79*(4), 319–328. https://doi.org/10.1002/ajh.20381

Ghinai, R. A., Mahmood, S., Mukonoweshuro, P., Webber, S., Wechalekar, A. D., & Moore, S. E. (2017). Diagnosing light chain amyloidosis on temporal artery biopsies for suspected giant cell arteritis. *Journal of Neuro-Ophthalmology, 37*(1), 34–39. https://doi.org/10.1097/WNO.0000000000000447

Grogan, M., Dispenzieri, A., & Gertz, M. A. (2017). Light-chain cardiac amyloidosis: Strategies to promote early diagnosis and cardiac response. *Heart, 103*(14), 1065–1072. https://doi.org/10.1136/heartjnl-2016-310704

Guidelines Working Group of UK Myeloma Forum, & British Committee for Standards in Haematology British Society for Haematology. (2004). Guidelines on the diagnosis and management of AL amyloidosis. *British Journal of Haematology, 125*(6), 681–700. https://doi.org/10.1111/j.1365-2141.2004.04970.x

Iida, T., Yamano, H., & Nakase, H. (2018). Systemic amyloidosis with gastrointestinal involvement: Diagnosis from endoscopic and histological views. *Journal of Gastroenterology and Hepatology, 33*(3), 583–590. https://doi.org/10.1111/jgh.13996

Jun, H. J., Kim, K., Kim, S. J., Mun, Y. C., Bang, S. M., Won, J. H.,... Korean Multiple Myeloma Working Party. (2013). Clinical features and treatment outcome of primary systemic light-chain amyloidosis in Korea: Results of multicenter analysis. *American Journal of Hematology, 88*(1), 52–55. https://doi.org/10.1002/ajh.23333

Kanaan, M. Z., Lorenzi, A. R., Thampy, N., Pandit, R., & Dayan, M. (2017). Bilateral non-arteritic anterior ischaemic optic neuropathy as the presentation of systemic amyloidosis. *Neuro-Ophthalmology, 41*(6), 330–334. https://doi.org/10.1080/01658107.2017.1328604

Kastritis, E., & Dimopoulos, M. A. (2016). Recent advances in the management of AL amyloidosis. *British Journal of Haematology, 172*(2), 170–186. https://doi.org/10.1111/bjh.13805

Kourelis, T. V., Kumar, S. K., Gertz, M. A., Lacy, M. Q., Buadi, F. K., Hayman, S. R.,...Dispenzieri, A. (2013). Coexistent multiple myeloma or increased bone marrow plasma cells define equally high-risk populations in patients with immunoglobulin light chain amyloidosis. *Journal of Clinical Oncology, 31*(34), 4319–4324. https://doi.org/10.1200/JCO.2013.50.8499

Kumar, S., Dispenzieri, A., Katzmann, J. A., Larson, D. R., Colby, C. L., Lacy, M. Q.,...Gertz, M. A. (2010). Serum immunoglobulin free light-chain measurement in primary amyloidosis: Prognostic value and correlations with clinical features. *Blood, 116*(24), 5126–5129. https://doi.org/10.1182/blood-2010-06-290668

Kumar, S., Dispenzieri, A., Lacy, M. Q., Hayman, S. R., Buadi, F. K., Colby, C.,...Gertz, M. A. (2012). Revised prognostic staging system for light chain amyloidosis incorporating cardiac biomarkers and serum free light chain measurements. *Journal of Clinical Oncology, 30*(9), 989–995. https://doi.org/10.1200/JCO.2011.38.5724

Kyle, R. A., Gertz, M. A., Greipp, P. R., Witzig, T. E., Lust, J. A., Lacy, M. Q., & Therneau, T. M. (1997). A trial of three regimens for primary amyloidosis: Colchicine alone, melphalan and prednisone, and melphalan, prednisone, and colchicine. *New England Journal of Medicine, 336*(17), 1202–1207. https://doi.org/10.1056/NEJM199704243361702

Kyle, R. A., Greipp, P. R., & O'Fallon, W. M. (1986). Primary systemic amyloidosis: Multivariate analysis for prognostic factors in 168 cases. *Blood, 68*(1), 220–224. Retrieved from https://www.ncbi.nlm.nih.gov/pubmed/3719098

Lachmann, H. J., Gallimore, R., Gillmore, J. D., Carr-Smith, H. D., Bradwell, A. R., Pepys, M. B., & Hawkins, P. N. (2003). Outcome in systemic AL amyloidosis in relation to changes in concentration of circulating free immunoglobulin light chains following chemotherapy. *British Journal of Haematology, 122*(1), 78–84. Retrieved from https://www.ncbi.nlm.nih.gov/pubmed/12823348

Li, T., Huang, X., Cheng, S., Zhao, L., Ren, G., Chen, W.,...Liu, Z. (2017). Utility of abdominal skin plus subcutaneous fat and rectal mucosal biopsy in the diagnosis of AL amyloidosis with renal involvement. *PloS One, 12*(9), e0185078. https://doi.org/10.1371/journal.pone.0185078

Lousada, I., Comenzo, R. L., Landau, H., Guthrie, S., & Merlini, G. (2015). Light chain amyloidosis: Patient experience survey from the amyloidosis research consortium. *Advances in Therapy, 32*(10), 920–928. https://doi.org/10.1007/s12325-015-0250-0

Madan, S., Dispenzieri, A., Lacy, M. Q., Buadi, F., Hayman, S. R., Zeldenrust, S. R.,...Kumar, S. K. (2010). Clinical features and treatment response of light chain (AL) amyloidosis diagnosed in patients with previous diagnosis of multiple myeloma. *Mayo Clinic Proceedings, 85*(3), 232–238. https://doi.org/10.4065/mcp.2009.0547

McCausland, K. L., White, M. K., Guthrie, S. D., Quock, T., Finkel, M., Lousada, I., & Bayliss, M. S. (2018). Light chain (AL) amyloidosis: The journey to diagnosis. *Patient, 11*(2), 207–216. https://doi.org/10.1007/s40271-017-0273-5

Merlini, G., & Bellotti, V. (2003). Molecular mechanisms of amyloidosis. *New England Journal of Medicine, 349*(6), 583–596. https://doi.org/10.1056/NEJMra023144

Merlini, G., & Palladini, G. (2008). Amyloidosis: Is a cure possible? *Annals of Oncology, 19(suppl 4)*, iv63–iv66. https://doi.org/10.1093/annonc/mdn200

Merlini, G., & Palladini, G. (2012). Differential diagnosis

of monoclonal gammopathy of undetermined significance. *Hematology: The Education Program of the American Society of Hematology, 2012*, 595–603. https://doi.org/10.1182/asheducation-2012.1.595

Merlini, G., Wechalekar, A. D., & Palladini, G. (2013). Systemic light chain amyloidosis: An update for treating physicians. *Blood, 121*(26), 5124–5130. https://doi.org/10.1182/blood-2013-01-453001

Michael, M., Kastritis, E., Delimpassi, S., Michalis, E., Repoussis, P., Kyrtsonis, M. C.,...Greek Myeloma Study Group. (2010). Clinical characteristics and outcome of primary systemic light-chain amyloidosis in Greece. *Clinical Lymphoma, Myeloma & Leukemia, 10*(1), 56–61. https://doi.org/10.3816/CLML.2010.n.006

Milani, P., Merlini, G., & Palladini, G. (2018). Light chain amyloidosis. *Mediterranean Journal of Hematology and Infectious Diseases, 10*(1), e2018022. https://doi.org/10.4084/MJHID.2018.022

Morris, K. L., Tate, J. R., Gill, D., Kennedy, G., Wellwood, J., Marlton, P.,...Mollee, P. (2007). Diagnostic and prognostic utility of the serum free light chain assay in patients with AL amyloidosis. *Internal Medicine Journal, 37*(7), 456–463. https://doi.org/10.1111/j.1445-5994.2007.01368.x

Muchtar, E., Derudas, D., Mauermann, M., Liewluck, T., Dispenzieri, A., Kumar, S. K.,...Gertz, M. A. (2016). Systemic immunoglobulin light chain amyloidosis-associated myopathy: Presentation, diagnostic pitfalls, and outcome. *Mayo Clinic Proceedings, 91*(10), 1354–1361. https://doi.org/10.1016/j.mayocp.2016.06.027

Muchtar, E., Dispenzieri, A., Lacy, M. Q., Buadi, F. K., Kapoor, P., Hayman, S. R.,...Gertz, M. A. (2017a). Overuse of organ biopsies in immunoglobulin light chain amyloidosis (AL): The consequence of failure of early recognition. *Annals of Medicine, 49*(7), 545–551. https://doi.org/10.1080/07853890.2017.1304649

Muchtar, E., Gertz, M. A., Kumar, S. K., Lacy, M. Q., Dingli, D., Buadi, F. K.,...Dispenzieri, A. (2017b). Improved outcomes for newly diagnosed AL amyloidosis between 2000 and 2014: Cracking the glass ceiling of early death. *Blood, 129*(15), 2111–2119. https://doi.org/10.1182/blood-2016-11-751628

National Comprehensive Cancer Network. (2018). Referenced with permission from the NCCN Clinical Practice Guidelines in Oncology (NCCN Guidelines®) for Systemic Light Chain Amyloidosis V.1.2019. © National Comprehensive Cancer Network, Inc. 2018. All rights reserved. Accessed October 26, 2018. To view the most recent and complete version of the guideline, go online to NCCN.org. NCCN makes no warranties of any kind whatsoever regarding their content, use or application and disclaims any responsibility for their application or use in any way. Retrieved from website.

Palladini, G., Jaccard, A., Milani, P., Lavergne, D., Foli, A., Bender, S.,...Merlini, G. (2017). Circulating free light chain measurement in the diagnosis, prognostic assessment and evaluation of response of AL amyloidosis: comparison of Freelite and N latex FLC assays. *Clinical Chemistry and Laboratory Medicine, 55*(11), 1734–1743. https://doi.org/10.1515/cclm-2016-1024

Palladini, G., & Merlini, G. (2016). What is new in diagnosis and management of light chain amyloidosis? *Blood, 128*(2), 159–168. https://doi.org/10.1182/blood-2016-01-629790

Palladini, G., Milani, P., & Merlini, G. (2015). Novel strategies for the diagnosis and treatment of cardiac amyloidosis. *Expert Review of Cardiovascular Therapy, 13*(11), 1195–1211. https://doi.org/10.1586/14779072.2015.1093936

Phull, P., Sanchorawala, V., Connors, L. H., Doros, G., Ruberg, F. L., Berk, J. L., & Sarosiek, S. (2018). Monoclonal gammopathy of undetermined significance in systemic transthyretin amyloidosis (ATTR). *Amyloid, 25*(1), 62–67. https://doi.org/10.1080/13506129.2018.1436048

Quarta, C. C., Gonzalez-Lopez, E., Gilbertson, J. A., Botcher, N., Rowczenio, D., Petrie, A.,...Gillmore, J. D. (2017). Diagnostic sensitivity of abdominal fat aspiration in cardiac amyloidosis. *European Heart Journal, 38*(24), 1905–1908. https://doi.org/10.1093/eurheartj/ehx047

Quock, T. P., Yan, T., Chang, E., Guthrie, S., & Broder, M. S. (2018). Epidemiology of AL amyloidosis: A real-world study using US claims data. *Blood Advances, 2*(10), 1046–1053. https://doi.org/10.1182/bloodadvances.2018016402

Rajkumar, S. V., Gertz, M. A., & Kyle, R. A. (1998). Primary systemic amyloidosis with delayed progression to multiple myeloma. *Cancer, 82*(8), 1501–1505.

Reynolds, M. M., Veverka, K. K., Gertz, M. A., Dispenzieri, A., Zeldenrust, S. R., Leung, N., & Pulido, J. S. (2017). Ocular manifestations of systemic amyloidosis. *Retina, 38*(7), 1371–1376. https://doi.org/10.1097/IAE.0000000000001901

Siddiqi, O. K., & Ruberg, F. L. (2018). Cardiac amyloidosis: An update on pathophysiology, diagnosis, and treatment. *Trends in Cardiovascular Medicine, 28*(1), 10–21. https://doi.org/10.1016/j.tcm.2017.07.004

Sidiqi, M. H., Aljama, M. A., Buadi, F. K., Warsame, R. M., Lacy, M. Q., Dispenzieri, A.,...Gertz, M. A. (2018). Stem cell transplantation for light chain amyloidosis: Decreased early mortality over time. *Journal of Clinical Oncology, 36*(13), 1323–1329. https://doi.org/10.1200/JCO.2017.76.9554

Sipe, J. D., Benson, M. D., Buxbaum, J. N., Ikeda, S., Merlini, G., Saraiva, M. J., & Westermark, P. (2014). Nomenclature 2014: Amyloid fibril proteins and clinical classification of the amyloidosis. *Amyloid, 21*(4), 221–224. https://doi.org/10.3109/13506129.2014.964858

Skinner, M., Sanchorawala, V., Seldin, D. C., Dember, L. M., Falk, R. H., Berk, J. L.,...Wright, D. G. (2004). High-dose melphalan and autologous stem-cell transplantation in patients with AL amyloidosis: An 8-year study. *Annals of Internal Medicine, 140*(2), 85–93. Retrieved from https://www.ncbi.nlm.nih.gov/pubmed/14734330

Vesole, D. H., Perez, W. S., Akasheh, M., Boudreau, C., Reece, D. E., Bredeson, C. N., & Plasma Cell Disorders Working Committee of the Center for International Blood and Marrow Transplant Research. (2006). High-dose therapy and autologous hematopoietic stem cell transplantation for patients with primary systemic amyloidosis: A Center for International Blood and Marrow Transplant Research Study. *Mayo Clinic Proceedings, 81*(7), 880–888. https://doi.org/10.4065/81.7.880

Wechalekar, A. D., Schonland, S. O., Kastritis, E., Gillmore, J. D., Dimopoulos, M. A., Lane, T.,...Palladini, G. (2013). A European collaborative study of treatment outcomes in 346 patients with cardiac stage III AL amyloidosis. *Blood, 121*(17), 3420–3427. https://doi.org/10.1182/blood-2012-12-473066