

Expert Insights on Triple-Negative Breast Cancer: Preparing for the Next Wave of Treatments

PRESENTED BY HEATHER R. GREENE, MSN, FNP, AOCNP®, and LEE S. SCHWARTZBERG, MD, FACP

From West Cancer Center & Research Institute, Memphis, Tennessee

Presenters' disclosures of conflicts of interest are found at the end of this article.

<https://doi.org/10.6004/jadpro.2020.11.3.10>

© 2020 Harborside™

Abstract

Heather R. Greene, MSN, FNP, AOCNP®, and Lee S. Schwartzberg, MD, FACP, discussed the current and future treatment landscape for triple-negative breast cancer, including recent and emerging data on approved treatments, novel therapeutic options being investigated, and best practices for identifying and monitoring adverse events associated with PARP and immune checkpoint inhibitors at JADPRO Live 2019.

Triple-negative breast cancer is a cancer that tests negative for estrogen receptors, progesterone receptors, and excess HER2 protein. Significantly more aggressive than other molecular subtypes, triple-negative breast cancer carries the highest risk of mortality in both the early-stage and metastatic settings and accounts for 10% to 17% of all breast carcinomas. At JADPRO Live 2019, Heather R. Greene, MSN, FNP, AOCNP®, and Lee S. Schwartzberg, MD, FACP, of West Cancer Center & Research Institute, evaluated the clinical significance of recent and emerging data regarding the efficacy and safety of approved therapeutic options for triple-negative breast cancer. Ms. Greene and Dr. Schwartzberg also discussed strategies to identify and manage adverse

events associated with PARP inhibitors and immune checkpoint inhibitors used in patients with triple-negative breast cancer.

“Whenever you have a disease that’s defined by what it isn’t, it means we still don’t know a lot about it,” said Dr. Schwartzberg, Medical Director of the West Cancer Center in Memphis and the Chief Medical Officer for One Oncology. “However, there is a lot of awareness among the patient community, so when you’re first seeing a patient with triple-negative breast cancer, I think it’s important to reassure them that we have good therapies and that we can manage their disease well” (Figure 1).

EARLY-STAGE DISEASE

As Dr. Schwartzberg explained, in the early-stage setting, lumpectomy plus radiation therapy is the pre-

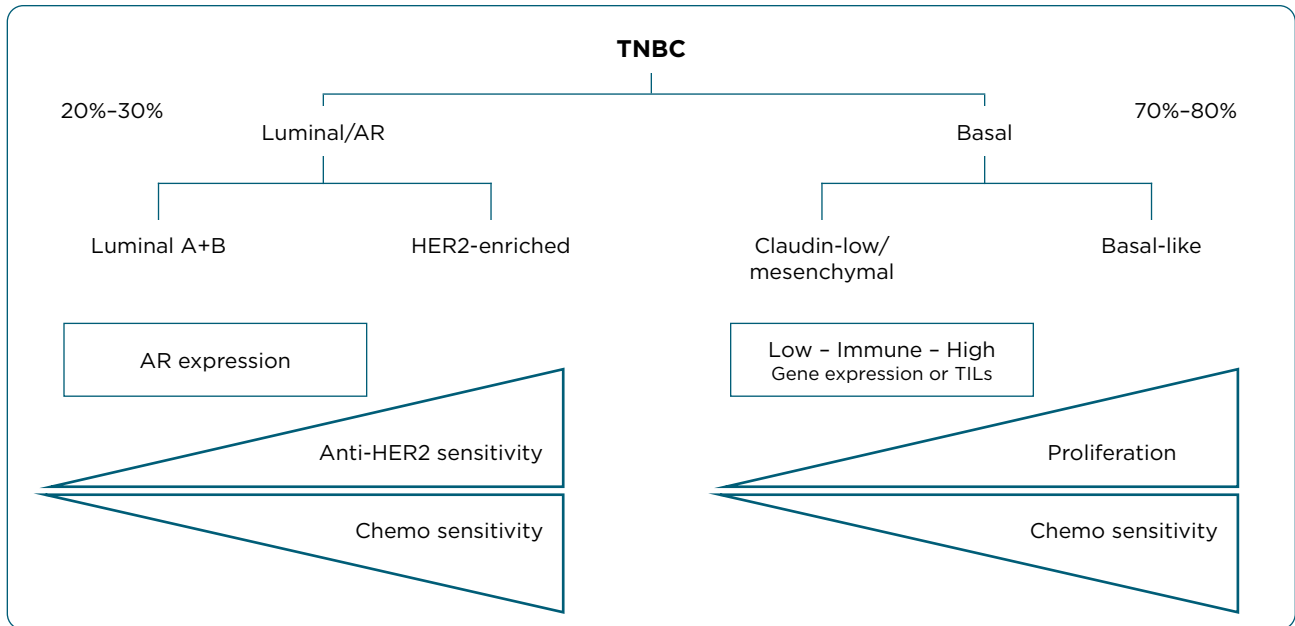


Figure 1. Stratification of triple-negative breast cancer. TNBC = triple-negative breast cancer; AR = androgen receptor; TILs = tumor-infiltrating lymphocytes.

ferred locoregional treatment. There is no advantage for mastectomy, which may in fact result in inferior outcomes, said Dr. Schwartzberg. For reasons of secondary prophylaxis, however, mastectomy is preferred in patients with *BRCA1/2* germline mutations.

Neoadjuvant chemotherapy has also become standard of care except for small cancers or for those who are ineligible. The use of sequential anthracycline cyclophosphamide followed by taxane yields a pathologic complete response in approximately one third of patients, said Dr. Schwartzberg, and another 10% to 15% of patients achieve a near pathologic complete response. While the addition of carboplatin to anthracycline plus taxane-based chemotherapy has been shown to improve pathologic response to 54% to 58%, there is increased toxicity associated with this regimen, and survival data are still pending.

As Dr. Schwartzberg reported, achievement of pathologic complete response is associated with excellent 3-to-5-year event-free survival and overall survival, while lack of pathologic complete response is associated with high recurrence risk (Cortazar et al., 2014).

Immunotherapy may also be an effective neoadjuvant therapy for early-stage triple-negative breast cancer. Results of the phase III KEY-

NOTE-522 study showed that the addition of pembrolizumab to chemotherapy boosted pathologic complete response rates compared with chemotherapy alone, regardless of PD-L1 status (Schmid et al., 2018). At a median follow-up of 18 months, said Dr. Schwartzberg, there was also a 6% improvement in event-free survival.

“This is not statistically significant yet—we have to follow this trial a little further—but it is encouraging,” said Dr. Schwartzberg, who noted that pembrolizumab is not yet approved in the adjuvant setting.

For patients who do not achieve a pathologic complete response, Dr. Schwartzberg noted that many clinicians are now using capecitabine in the adjuvant setting after preoperative chemotherapy (Masuda et al., 2017).

ADVANCED DISEASE

As Dr. Schwartzberg explained, despite effective therapies available in the early-stage setting, there is often rapid progression from distant recurrence to death. With a median overall survival of 12 to 18 months, metastatic triple-negative breast cancer carries a poor prognosis, and response rates worsen with each line of therapy.

In general, National Comprehensive Cancer Network (NCCN) Guidelines recommend that

patients with metastatic breast cancer get singlet therapies and sequential singlet therapies, said Dr. Schwartzberg, although patients with high tumor burden may benefit from a doublet therapy. When platinum agents have not been used in the neoadjuvant setting, Dr. Schwartzberg noted that they are often used in the first-line metastatic setting, but both platinum-based and taxane chemotherapies have demonstrated similar responses.

“Unfortunately, chemotherapy has only modest activity,” said Dr. Schwartzberg, who noted that data from the TNT trial showed approximately 30% response rates with both carboplatin and docetaxel in the first-line setting (Tutt et al., 2018).

In the absence of a germline or a somatic *BRCA* mutation, a taxane should remain the first-line treatment of choice for chemotherapy, Dr. Schwartzberg noted. Data from the TNT trial showed that patients with a germline *BRCA* mutation performed better with carboplatin.

RECENTLY APPROVED AND/OR EMERGING THERAPIES

According to Dr. Schwartzberg, patients with HER2-negative disease should strongly consider *BRCA1* and *BRCA2* germline testing before starting therapy based on data from the OlympiAD trial. Patients with germline *BRCA* mutations and HER2-negative disease, including hormone receptor-positive and triple-negative breast cancer, had a 3-month improvement in progression-free survival on olaparib, a PARP inhibitor, vs. chemotherapy (Robson et al., 2017).

There was also a trend towards improvement in overall survival, but it was not statistically significant, said Dr. Schwartzberg, who noted that talazoparib, another PARP inhibitor, showed a similar 3-month improvement in progression-free survival vs. chemotherapy in the EMBRACA study (Litton et al., 2018).

“In general, the toxicity associated with PARP inhibitors is much less than chemotherapy in these trials,” said Dr. Schwartzberg. “If you have a germline *BRCA*-mutated patient, you should strongly consider treating with a PARP inhibitor before chemotherapy, and that’s true for the triple-negative breast cancers.”

PD-L1 INHIBITORS

Patients with triple-negative breast cancer should also be assessed for PD-L1 biomarker status, said Dr. Schwartzberg, based on data from the IMPassion130 study, which was the first trial to show a definite benefit with the addition of an immune checkpoint inhibitor (atezolizumab) to chemotherapy (nab-paclitaxel; Schmid et al., 2019).

Across the intent-to-treat population, the combination of atezolizumab and nab-paclitaxel showed a 3-month improvement in overall survival vs. nab-paclitaxel alone. What’s more, said Dr. Schwartzberg, among patients with PD-L1-positive status, there was a 30% improvement in overall survival, “which is about as good as we would expect.” Atezolizumab was approved by the U.S. Food & Drug Administration (FDA) in March in combination with nab-paclitaxel for locally advanced triple-negative breast cancer with a companion diagnosis.

OTHER DRUGS

Clinicians now have two classes of drugs available in the advanced setting (PARP inhibitors for germline *BRCA*-mutated disease and atezolizumab for PD-L1 positive disease), but that still leaves a large population of patients who don’t have those biomarkers. As Dr. Schwartzberg reported, preclinical data suggest that androgen inhibitors could work in breast cancer in a similar fashion to the way they work in prostate cancer. In androgen receptor-expressing triple-negative breast cancer, enzalutamide, an androgen receptor inhibitor, demonstrated a clinical benefit in approximately 25% of patients, and future research is being conducted (Traina et al., 2018).

Clinicians are also excited about an antibody-drug conjugate called sacituzumab govitecan, which has demonstrated efficacy in heavily pretreated patients (Bardia et al., 2019). Many patients had some benefit from sacituzumab, said Dr. Schwartzberg, who noted that the clinical benefit rate, meaning stable disease or better at 6 months, was 45%, and there were even some complete responses in clinical trials.

ADVERSE EVENTS ASSOCIATED WITH PARP INHIBITORS

Ms. Greene, an oncology nurse practitioner and a sub-investigator, noted that 97% of patients expe-

rienced some adverse event in the OlympiAD trial, but rates of grade 3 or 4 events on PARP inhibition were lower than the control arm (37% vs. 51%). Although 25% of patients required dose reductions due to adverse events, the only grade 3 or 4 toxicity experienced by more than 10% of patients on olaparib was anemia (14%), and only 5% required permanent discontinuation (Table 1).

There is also a warning for the potential to develop myelodysplastic syndrome or acute leukemia, said Ms. Greene, who noted, however, that this occurred in less than 1.5% of patients on trial.

“This is something that we need to keep in mind, knowing that a lot of these patients can develop significant myelosuppression that improves when we hold the drug or dose reduce or delay,” she explained. “There’s also less than 1% risk of pneumonitis, which would require permanent discontinuation.”

In addition, PARP inhibitors are potentially teratogenic, so if patients have not already had their ovaries removed, said Ms. Greene, they need to maintain contraception use during therapy for at least 6 months after completing therapy.

According to Ms. Greene, patients should know to call their providers for the following side effects: severe weakness, fever, signs of infection, blood in urine/stool, uncommon bruising or bleeding that doesn’t stop, shortness of breath, cough, nausea/vomiting, or diarrhea.

“Patients on PARP inhibitors should have a complete blood count (CBC) at baseline and then on a monthly basis,” said Ms. Greene. “Advanced practitioners should also have a high index of suspicion for pneumonitis or acute myeloid leukemia.”

IMMUNE-RELATED ADVERSE EVENTS WITH IMMUNE CHECKPOINT INHIBITORS

As Ms. Greene explained, immune-related adverse events are completely different than those associated with chemotherapy. Although most are mild and easily manageable with steroids, some adverse events can be severe, life threatening, and irreversible. Moreover, the toxicities associated with immunotherapy can affect any organ system in the body, and these side effects may develop up to 1 year after therapy discontinuation (Table 2). “We’re used to associating immune-related ad-

Table 1. OlympiAD: Adverse Events Associated With Olaparib (> 20% Patients)

Event	All grades (%)	Grades 3/4 (%)
Anemia	40	16
Neutropenia	27	9
Nausea	58	0
Vomiting	30	0
Diarrhea	21	0.5
Fatigue	29	3
Headache	20	1
Respiratory tract infections	27	1

Note. Information from AstraZeneca (2019); Caulfield et al. (2019).

verse events with rash, arthralgia, fatigue, hepatitis, pneumonitis, and colitis, but when you have patients on immune checkpoint inhibitors, you have to be cautious of other symptoms and work those up very thoroughly because nothing is off limits,” said Ms. Greene.

The NCCN Guidelines recommend a complete physical exam, head-to-toe CT imaging, an MRI if indicated, and a brain MRI to rule out brain metastases. Blood work includes a CBC, comprehensive metabolic panel, serum cortisol, and thyroid panel. Certain patients may also need individualized cardiovascular or pulmonary workup that’s more extensive, along with a thorough dermatologic and musculoskeletal evaluation. As with PARP inhibitors, patient education is critical, said Ms. Greene, who emphasized that advanced practitioners play a unique role in educating patients and caregivers about toxicities and management.

“It’s important to make sure that when patients are starting on these therapies they’re provided with the information they need,” said Ms. Green. “Patients need to know what to look for at home so that they can call the clinic and share any problems they may be experiencing.” ●

Disclosure

Dr. Schwartzberg has consulted with Amgen, AstraZeneca, Genentech/Roche, and Pfizer. Ms. Greene is on the speakers bureau for Pfizer. This symposium was supported by an educational grant from Merck Sharp & Dohme Corp.

Table 2. ASCO/NCCN 2019 Guidelines for Managing Immune-Related Adverse Events

Toxicity grade	Recommendation
1	<ul style="list-style-type: none"> Continue checkpoint inhibitors with close monitoring, with exception of some neurologic, hematologic, and cardiac toxicities
2	<ul style="list-style-type: none"> Hold for most grade 2 toxicities and consider resuming when symptoms and/or laboratory values return to grade 1 or less Corticosteroids (initial dose of 0.5 to 1 mg/kg/d of prednisone or equivalent) may be given
3	<ul style="list-style-type: none"> Hold checkpoint inhibitors for grade 3 adverse events and initiate high-dose corticosteroids (prednisone 1 to 2 mg/kg/d or methylprednisolone IV 1 to 2 mg/kg/d) <ul style="list-style-type: none"> » Taper corticosteroids over course of at least 4 to 6 weeks » If symptoms do not improve with 48 to 72 hours of high-dose corticosteroid, infliximab may be offered for some toxicities
4	<ul style="list-style-type: none"> Warrants permanent discontinuation of checkpoint inhibitors, with exception of endocrinopathies controlled by hormone replacement

Note. Information from Brahmer et al. (2018); Postow et al. (2018).

References

- AstraZeneca. (2019). Lynparza (olaparib) package insert. Retrieved from http://www.azpicentral.com/pi.html?product=lynparza_tb&country=us&popup=no
- Bardia, A., Mayer, I. A., Vahdat, L. T., Tolaney, S. M., Isakoff, S. J., & Diamond, J. R. (2019). Sacituzumab govitecan-hzyi in refractory metastatic triple-negative breast cancer. *New England Journal of Medicine*, *380*(8), 741–751. <http://doi.org/10.1056/NEJMoa1814213>
- Brahmer, J. R., Lacchetti, C., Schneider, B., Atkins, M. B., Brassil, K. J., Caterino, J. M.,...Thompson, J. A. (2018). Management of immune-related adverse events in patients treated with immune checkpoint inhibitor therapy: American Society of Clinical Oncology Clinical Practice Guideline. *Journal of Clinical Oncology*, *36*(17), 1714–1768. <https://doi.org/10.1200/jco.2017.77.6385>
- Caulfield, S. E., Davis, C. C., & Byers, K. F. (2019). Olaparib: A novel therapy for metastatic breast cancer in patients with a BRCA1/2 mutation. *Journal of the Advanced Practitioner in Oncology*, *10*(2), 167–174. <https://doi.org/10.6004/jadpro.2019.10.2.6>
- Cortazar, P., Zhang, L., Untch, M., Mehta, K., Costantino, J. P., Wolmark, N.,...von Minckwitz, G. (2014). Pathological complete response and long-term clinical benefit in breast cancer: The CTNeoBC pooled analysis. *Lancet*, *384*(9938), 164–172. [http://doi.org/10.1016/S0140-6736\(13\)62422-8](http://doi.org/10.1016/S0140-6736(13)62422-8)
- Litton, J. K., Rugo, H. S., Ettl, J., Hurvitz, S. A., Goncalves, A., Lee, K. H.,...Blum, M. L. (2018). Talazoparib in patients with advanced breast cancer and a germline BRCA Mutation. *New England Journal of Medicine*, *379*(8), 753–763. <http://doi.org/10.1056/NEJMoa1802905>
- Masuda, N., Lee, S. J., Ohtani, S., Im, Y. H., Lee, E. S., Yokota, I.,...Toi, M. (2017). Adjuvant capecitabine for breast cancer after preoperative chemotherapy. *New England Journal of Medicine*, *376*(22), 2147–2159. <http://doi.org/10.1056/NEJMoa1612645>
- Postow, M. A., Sidlow, R., & Hellmann, M. D. (2018). Immune-related adverse events associated with immune checkpoint blockade. *New England Journal of Medicine*, *378*, 158–168. <https://doi.org/10.1056/NEJMra1703481>
- Robson, M., Im, S. A., Senkus, E., Xu, B., Domchek, S. M., Masuda, N.,...Conte, P. (2017). Olaparib for metastatic breast cancer in patients with a germline BRCA mutation. *New England Journal of Medicine*, *377*(6), 523–533. <http://doi.org/10.1056/NEJMoa1706450>
- Schmid, P., Adams, S., Rugo, H. S., Schneeweiss, A., Barrios, C. H., Iwata, H.,...Emens, L. A. (2019). IMpassion130: Updated overall survival (OS) from a global, randomized, double-blind, placebo-controlled, phase III study of atezolizumab (atezo) + nab-paclitaxel (nP) in previously untreated locally advanced or metastatic triple-negative breast cancer (mTNBC). *Journal of Clinical Oncology*, *37*(15), 1003–1003. http://doi.org/10.1200/JCO.2019.37.15_suppl.1003
- Schmid, P., Cortés, J., Bergh, J. C. S., Pusztai, L., Denkert, C., Verma, S.,...Dent, A. (2018). KEYNOTE-522: Phase III study of pembrolizumab + chemotherapy vs placebo + chemo as neoadjuvant treatment, followed by pembrolizumab vs placebo as adjuvant treatment for early triple-negative breast cancer. *Journal of Clinical Oncology*, *36*(15). http://doi.org/10.1200/JCO.2018.36.15_suppl.TPS602
- Traina, T. A., Miller, K., Yardley, D. A., Eakle, J., Schwartzberg, L. S., O'Shaughnessy, J.,...Cortes, J. (2018). Enzalutamide for the treatment of androgen receptor-expressing triple-negative breast cancer. *Journal of Clinical Oncology*, *36*(9), 884–890. <http://doi.org/10.1200/JCO.2016.71.3495>
- Tutt, A., Tovey, H., Cheang, M. C. U., Kernaghan, S., Kilburn, L., Gazinska, P.,...Bliss, J. M. (2018). Carboplatin in BRCA1/2-mutated and triple-negative breast cancer BRCAness subgroups: The TNT trial. *Nature Medicine*, *24*(5), 628–637. <http://doi.org/10.1038/s41591-018-0009-7>