

# Surgical Management of Gastrointestinal Stromal Tumors

HEATHER TOWNSEND, MPAP, PA-C

From Atrium Health Carolinas Medical Center, Charlotte, North Carolina

Author's disclosure of conflict of interest is found at the end of this article.

Correspondence to: Heather Townsend, MPAP, PA-C, 1000 Blythe Boulevard, Charlotte, NC 28203  
E-mail: h.drephal@gmail.com

<https://doi.org/10.6004/jadpro.2023.14.6.7>

© 2023 BroadcastMed LLC

## Abstract

Gastrointestinal stromal tumors (GISTs) are considered rare, but they are one of the most common malignant mesenchymal tumors within the gastrointestinal tract, affecting 4,000 to 6,000 adults in the United States each year. Because gastrointestinal bleeding is often the initial symptom, a thorough and timely diagnostic workup is imperative to accurately diagnose a potentially deadly tumor. Endoscopic ultrasound is helpful when working through a differential diagnosis of subepithelial lesions and can help identify which mucosal layer the lesion originates from, as well as the density of the lesion; however, surgical resection is the standard of care for the treatment of a resectable nonmetastatic GIST. For recurrent GISTs, metastatic disease, or GISTs not amenable to resection, tyrosine kinase inhibitors are frequently used, with imatinib being used in the first-line setting. A multimodal treatment approach is often necessary to increase the chances of a permanent cure.

## CASE STUDY

SY is an 86-year-old female who presented to the emergency department with an initial complaint of dizziness, fatigue, and generalized weakness over the past several days. Past medical history is significant for hyperlipidemia and esophagitis with esophageal structuring. Previous surgical history includes an open appendectomy and exploratory laparotomy over 50 years prior. Upon further history, she reports passing black stools for several days prior to the onset of dizziness. Workup in the emergency department demonstrated a hemoglobin of 6.1 g/dL, and she was subsequently admitted to the hospital for a blood transfusion and further workup of her bleeding that appeared to be consistent with an upper gastrointestinal source. She denied any prior history of similar complaints or a prior history of known gastrointestinal bleeding. Upon admission to the hospital, an esophagogastroduodenoscopy was performed and was notable for findings consistent with a submucosal mass in the gastric fundus. A CT scan of the abdomen and pelvis confirmed an intraluminal gastric mass with uniform enhancement.

**G**astrointestinal stromal tumors (GISTs) are considered rare, but they are one of the most common malignant mesenchymal tumors within the gastrointestinal tract. Approximately 4,000 to 6,000 adults will be diagnosed with a GIST in the United States each year (American Cancer Society, 2023). These mesenchymal tumors can occur anywhere throughout the gastrointestinal tract and originate from the interstitial cells of Cajal, located within the muscle layer, which are also referred to as the pacemaker cells of the gut. The proliferation of these cells is characterized by mutations in the tyrosine kinase receptor *KIT* and platelet-derived growth factor receptor alpha (*PDGFRA*; Søreide et al., 2016). Figure 1 illustrates the pathway of interstitial cells of Cajal maturation and tumor formation. These interstitial cells are essentially stem cells that only partially differentiate initially, but then later differentiate by *KIT* and insulin growth factor signaling. The formation of a GIST is a result of mutation and overexpression of the tyrosine kinase receptor *KIT* and *PDGFRA* (Akahoshi et al., 2018).

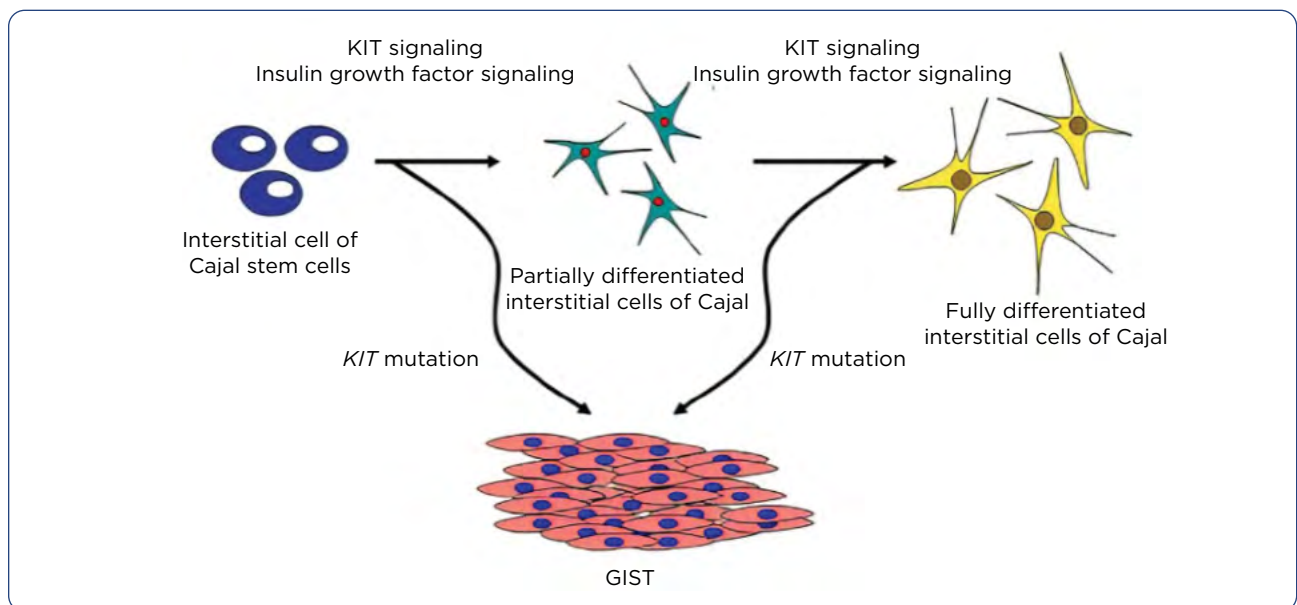
The median age of presentation of GIST is 60 years old, making SY older than the median age range of presentation. Data also show that there is equal distribution in males and females (Søreide et al., 2016). Although a GIST can occur anywhere in the gastrointestinal tract, they occur in the stomach

in about 50% of cases. Other common locations include the small bowel, colon, rectum, and esophagus (Akahoshi et al., 2018). Gastrointestinal stromal tumors are typically categorized based on morphologic type. The main types include spindle-shaped cell type, which is the most common, followed by epithelial cell type and mixed type. Histologic differentiation of SY's tumor demonstrated spindle-shaped cell type morphology, which is most common and occurs in about 70% of cases (van Roggen et al., 2001).

Approximately 10% to 30% of GISTs are malignant, with all having the potential for malignancy depending on their mitotic index. Rather than a GIST being classified as benign or malignant, they are characterized by clinical malignancy risk, which is very low, low, intermediate, or high (Akahoshi et al., 2018). These risk categories are part of the modified Fletcher's risk classification, which correlates to tumor site, mitotic index, and primary tumor size (Table 1). The site of the primary tumor is of particular relevance, as more distally located tumors are typically more aggressive. The risk classification is used to predict postoperative metastasis and ultimately guide the frequency of postoperative follow-up with CT imaging.

## DIAGNOSIS

SY initially presented with several days of dizziness, fatigue, generalized weakness, and melena. A



**Figure 1.** Pathway of interstitial cells of Cajal maturation and GIST formation. Modified with permission from Lorincz et al. (2008).

**Table 1. Modified Fletcher's Risk Classification**

Risk category	Tumor size (cm)	Mitotic index (per 50 HPFs)	Primary tumor site
Very low risk	< 2.0	≤ 5	Any
Low risk	2.1-5.0	≤ 5	Any
Intermediate risk	2.1-5.0	> 5	Gastric
	< 5.0	6-10	Any
	5.1-10.0	≤ 5	Gastric
High risk	Any	Any	Tumor rupture
	> 10.0	Any	Any
	Any	> 10	Any
	> 5.0	> 5	Any
	2.1-5.0	> 5	Non-gastric
	5.1-10.0	≤ 5	Non-gastric

Note. Modified with permission from Akahoshi et al. (2018).

complete blood count revealed that her hemoglobin was 6.1 g/dL which, in combination with her symptoms, suggested bleeding in the gastrointestinal tract. According to Joensuu and colleagues (2013), some of the most common symptoms of a GIST include gastrointestinal bleeding that presents as melena or hematochezia with subsequent anemia, generalized weakness, as well as abdominal pain and distension. Melena is typically indicative of upper gastrointestinal bleeding, which is defined as a hemorrhage originating proximal to the ligament of Treitz (Patel et al., 2013). Upper gastrointestinal bleeding should prompt evaluation by endoscopy. Although endoscopy is helpful to identify the source of bleeding, which in this case was a subepithelial lesion, it only provides a general description of the lesion and therefore, a GIST cannot be diagnosed with endoscopy alone. However, in some scenarios, such as an ulcerated tumor, endoscopy can prove to be diagnostic. With endoscopy, a GIST is described as a nonspecific, smooth lesion that is usually covered with normal mucosa (Akahoshi et al., 2018). Once a subepithelial lesion is identified on endoscopy, a differential diagnosis is broad and may include leiomyoma, schwannoma, lipoma, or even other, nontumor etiologies that may resemble subepithelial lesions, or cause gastrointestinal bleeding or generalized abdominal pain; these nontumor etiologies include ectopic pancreas, esophageal varices, bowel obstruction, or peptic ulcer disease (Figure 2).

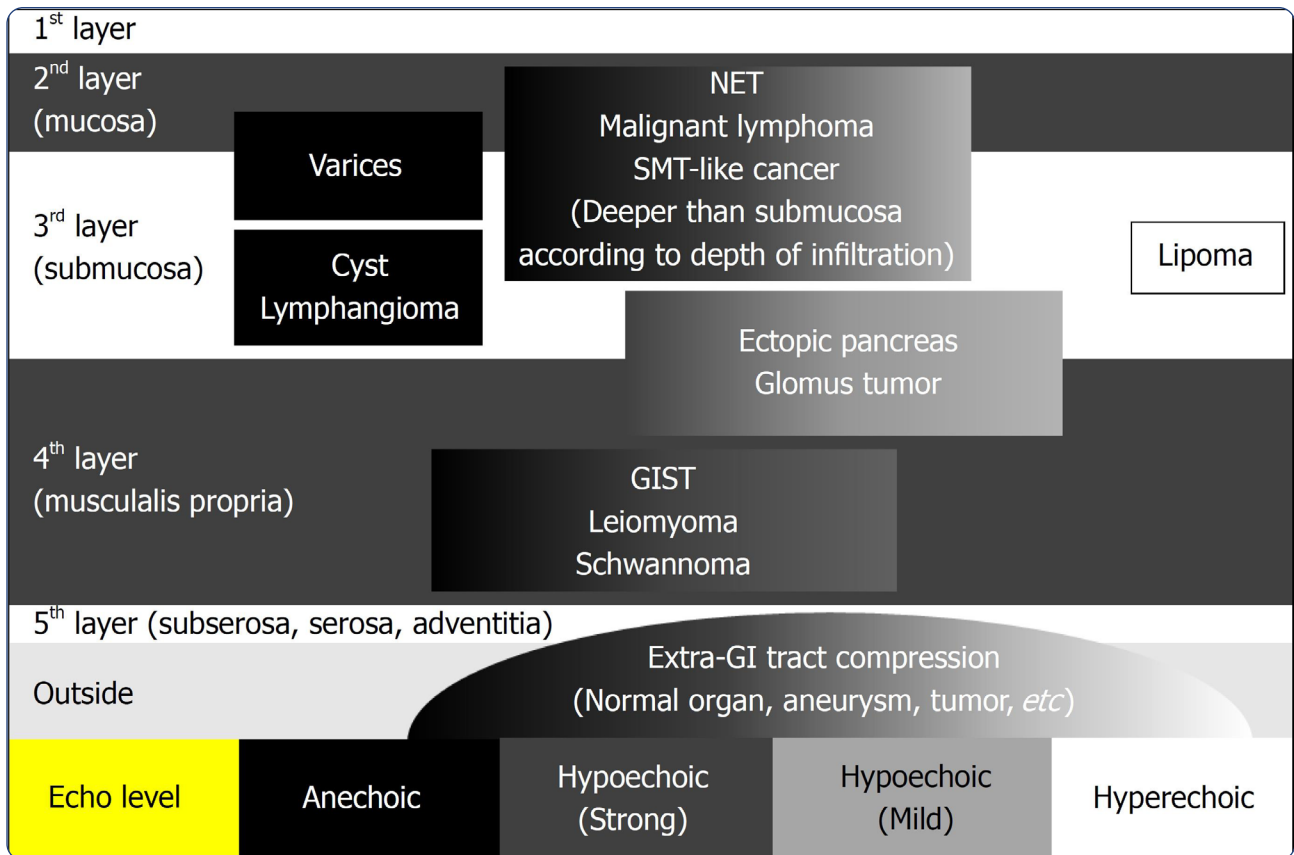
An endoscopic ultrasound is helpful when working through a differential diagnosis of subepithelial lesions and can provide information on which mucosal layer the lesion originates from, as well as the density of the lesion. Gastrointestinal stromal tumors are often described as a hypoechoic solid mass on an endoscopic ultrasound (Akahoshi et al., 2018). Although an endoscopic ultrasound is helpful in differentiating GISTs from other subepithelial lesions, it does not provide enough information to definitively diagnose.

Another imaging modality that may incidentally identify a GIST and is often obtained to better depict the intraluminal, mural, and extra-serosal components of a GIST, is a CT scan (Vernuccio et al., 2016). On a CT scan, a GIST will appear as an exophytic mass with variance in attenuation depending on the size of the tumor, which may help differentiate from a gastric adenocarcinoma. A conclusive diagnosis of a GIST is most accurately achieved by an endoscopic ultrasound-guided fine needle aspiration. A tissue sample is sent for histological evaluation and diagnosed based on the presence of *KIT*- or *CD34*-positive epithelial or spindle-shaped cells (Akahoshi et al., 2018). An endoscopic ultrasound should always be done prior to a biopsy because some subepithelial lesions can be potentially related to vascular disease, such as varices, in which case a biopsy would be contraindicated. Management of a subepithelial lesion should begin with further examination by endoscopic ultrasound and, depending on the density and additional characteristics of the lesion, fine needle aspiration should follow. A tissue sample of the lesion will further classify the lesion and guide subsequent treatment. The algorithm in Figure 3 is a helpful reference for the workup of subepithelial lesions. A definitive diagnosis of a GIST by histopathological evaluation is not required prior to proceeding with surgical resection; however, it is necessary prior to initiating systemic therapy.

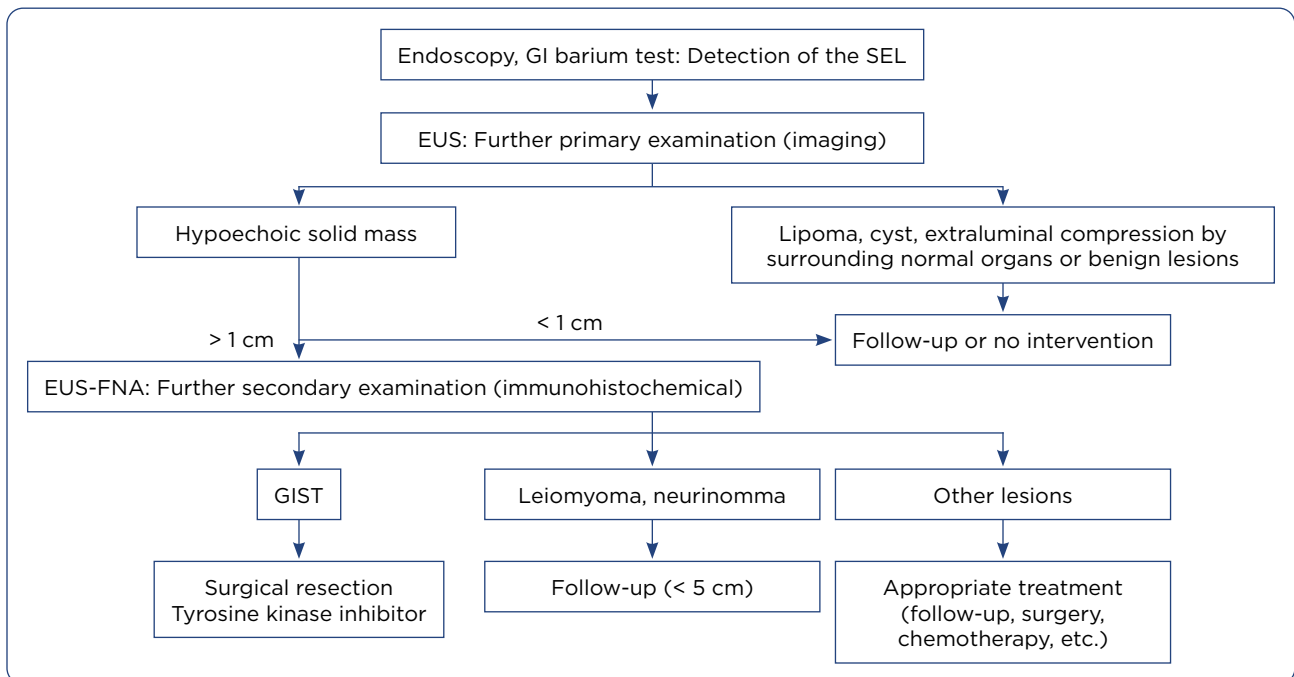
## TREATMENT

### Surgery

Surgical resection is the standard of care for the treatment of a resectable, nonmetastatic GIST. Literature has shown that laparoscopic resection is a safe and effective option for a gastric GIST; it is a minimally invasive technique with comparable



**Figure 2.** Differential diagnosis of subepithelial lesions by endoscopic ultrasound. Modified with permission from Akahoshi et al. (2018).



**Figure 3.** Algorithm to guide workup of subepithelial lesions. GI = gastrointestinal; SEL = subepithelial lesions; EUS = endoscopic ultrasound; FNA = fine needle aspiration; GIST = gastrointestinal stromal tumor. Modified with permission from Akahoshi et al. (2018).

outcomes to open surgery. There are several other minimally invasive options for managing these tumors, including submucosal tunneling endoscopic resection, endoscopic full thickness resection, and laparoscopic endoscopic cooperative surgery; however, they are not performed routinely and require additional data to investigate safety and prognosis (Akahoshi et al., 2018). Figure 4 shows the laparoscopic view of the tumor resection and postoperative endoscopy.

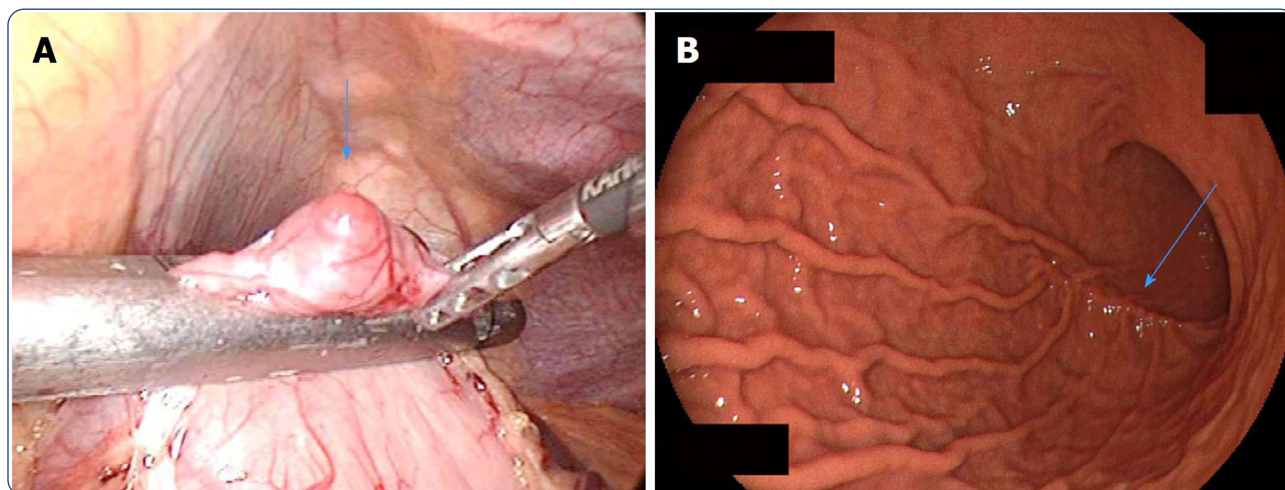
### Targeted Therapy

For recurrent GISTs, metastatic disease, or those that are not amendable to resection, tyrosine kinase inhibitors (TKIs) are frequently used. The mutational variability of GISTs has significant treatment implications and, therefore, the mainstay of systemic treatment is molecular-targeted therapy (Blay, 2010). The most common mutation harbored in GISTs includes *KIT* exon 11 point mutations, which makes up nearly 70% of cases (Kelly et al., 2021). In roughly 8% to 10% of cases, mutations are seen in *KIT* exon 9 and are typically associated with tumors in the small or large bowel. *PDGFRA* mutations account for roughly 10% of cases and are the second most common molecular subtype. Gastrointestinal stromal tumors harboring these mutations often arise in the stomach. The most frequently mutated region of *PDGFRA* is exon 18 and accounts for approximately 8% of GISTs. Within this subset, 70% arise

from *PDGFRA* exon 18 D842V mutations. About 10% to 15% of GISTs contain *KIT* and *PDGFRA* wild-type mutations and are related to genetic alternations in the Ras/mitogen-activated protein kinase (MAPK) pathway, which can be associated with neurofibromatosis type 1 or succinate dehydrogenase deficiency (Kelly et al., 2021).

Imatinib (Gleevec) is the first-line treatment for GISTs harboring *KIT* exon 11 and exon 9 mutations based on efficacy and safety. Literature has shown that *KIT* exon 11 mutants have a significantly higher response rate and overall survival rate with imatinib, compared with *KIT* exon 9 and *KIT* or *PDGFRA* wild-type mutants (Kelly et al., 2021). It is known that GISTs with *PDGFRA* exon 18 D842V mutations are resistant to imatinib; however, as of January 2020, patients with advanced or metastatic GISTs with *PDGFRA* exon 18 D842V mutations have been approved for treatment with avapritinib (Ayvakit), which is now considered first-line in this subset of patients (Huang et al., 2022). Prior to the approval of avapritinib, there was no targeted therapy for tumors with this particular mutation. This is a noteworthy advancement in therapy considering *PDGFRA* exon 18 D842V mutations account for nearly 70% of the *PDGFRA* subtype. It is important to note that GISTs harboring other *PDGFRA* mutations are typically responsive to imatinib.

In metastatic GISTs that fail treatment with imatinib, become resistant, or do not necessitate more specific molecular-targeted therapy, second-



**Figure 4.** Laparoscopic view of gastrointestinal stromal tumor resection and postoperative endoscopy. (A) Laparoscopic resection of a small GIST. (B) Postoperative endoscopy showing the site of resected tumor (blue arrow). Modified with permission from Akahoshi et al. (2018).



third-, and even fourth-line options exist; however, these have low response rates and limited clinical efficacy. These options include sunitinib (Sutent), regorafenib (Stivarga), and ripretinib (Qinlock), respectively. Higher response rates were observed in GISTs harboring *KIT* exon 9 mutations treated with sunitinib compared with *KIT* exon 11 mutants (Heinrich et al., 2008). Regorafenib was approved by the US Food and Drug Administration (FDA) in 2013 for the treatment of advanced GISTs that failed therapy of both imatinib and sunitinib (von Mehren & Joensuu, 2018). Ripretinib became FDA-approved in May 2020 and has been shown to target a broad range of mutants. This TKI is approved to initiate in patients with advanced GISTs who have previously progressed on three or more TKIs, including imatinib (Kelly et al., 2021).

As mentioned previously, surgery is often first-line treatment for resectable, nonmetastatic GISTs; however, surgical resection may also have a role in advanced disease. Literature suggests that treating advanced or metastatic GISTs with imatinib prior to surgical resection yields better outcomes (Lim & Tan, 2017). Neoadjuvant therapy is appropriate if attempting to debulk the tumor to prevent multivisceral resection, reduce resection morbidity, or even prevent potential tumor rupture; therefore, neoadjuvant therapy is often continued for as long as possible, as long as the tumor is responding or until the response plateaus. In the setting of a GIST rupture, it is recommended to initiate defined interval or lifelong adjuvant therapy with imatinib, as tumor rupture is predictive of recurrence even after complete surgical resection (Nishida et al., 2019).

While optimizing molecular-targeted TKI therapy is of utmost importance when treating GISTs, surgical resection of the primary tumor is also recommended. In the setting of metastatic disease, surgery can play a role in palliative management; however, additional randomized controlled trials are needed to evaluate the true benefit of surgery in advanced disease. Surgery with the purpose of palliation can be considered in patients who develop recurrent bowel obstructions or perforation. Metastasectomy can also be considered in patients who have previously had a good response to TKI therapy, specifically imatinib. One study demonstrated that patients with metastatic disease who underwent metastasec-

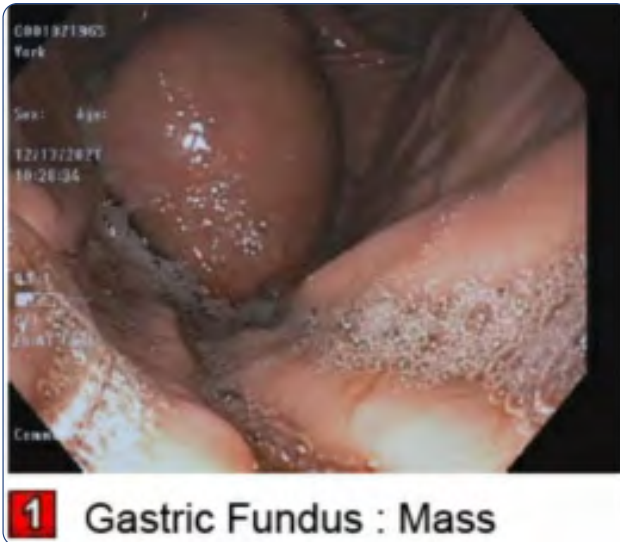tomy had survival rates that directly correlated to their disease status on imatinib. Essentially, patients who experienced good response to imatinib had higher survival rates after metastasectomy. This study showed that surgery may very well improve survival rates, but only in a select group of patients (Bamboate & DeMatteo, 2014).

In the setting of nonmetastatic disease and following primary tumor resection, postoperative metastasis risk is based on the modified Fletcher's risk classification. Follow-up is recommended with an abdominal CT scan with contrast to evaluate for local recurrence, peritoneal dissemination, or metastasis to the liver (Akahoshi et al., 2018). For GISTs that fall into the very low, low, and moderate risk categories, an abdominal CT scan is recommended every 6 months to 1 year. For GISTs that fall into the high-risk category or those complicated by metastasis, CT imaging should be obtained every 4 to 6 months. Studies have shown an optimistic outcome for these patients, with an estimated 59.9% 5-year recurrence-free survival rate after undergoing surgery (Akahoshi et al., 2018). Overall, an early diagnosis and prompt initiation of molecular-targeted TKI therapy, in addition to appropriate surgical intervention, is proven to deliver the best outcomes for patients with GISTs.

## CONCLUSION

SY was treated appropriately once it was diagnostically determined that her GIST was resectable. Per chart review, it does not appear that she underwent an endoscopic ultrasound, but she did undergo endoscopy that identified the subepithelial lesion, and a GIST, spindle cell type, was proven by histopathological examination. Once the diagnosis was confirmed, she underwent a laparoscopic, transgastric resection of the gastric mass with upper endoscopy (Figure 5).

Histopathological evaluation determined that SY's tumor was classified as G1: low grade with a mitotic rate of  $\leq 5/5 \text{ mm}^2$ ; therefore, she was not treated with a TKI prior to or following surgery. According to the modified Fletcher's risk classification, this means she will need an abdominal CT with contrast every 6 months to 1 year. Close observation and follow-up postoperatively is recommended for at least 10 years following surgery to assess for local recurrence, liver metastasis, or



**Figure 5.** Intraoperative image of SY's gastrointestinal stromal tumor during laparoscopic, transgastric resection of gastric mass.

peritoneal dissemination (Akahoshi et al., 2018). SY's case was handled appropriately with the collaboration of multiple health-care teams, including acute care surgery, gastroenterology, and pathology. Her primary tumor was successfully resected and promptly identified after an initial presentation of generalized weakness and melena. ●

### Disclosure

The author has no conflict of interest to disclose.

### References

- Akahoshi, K., Oya, M., Koga, T., & Shiratsuchi, Y. (2018). Current clinical management of gastrointestinal stromal tumor. *World Journal of Gastroenterology*, *24*(26), 2806–2817. <https://doi.org/10.3748/wjg.v24.i26.2806>
- American Cancer Society. (2023). Key statistics for gastrointestinal stromal tumors. <https://www.cancer.org/cancer/types/gastrointestinal-stromal-tumor/about/key-statistics.html>
- Bamboato, Z. M., & DeMatteo, R. P. (2014). Metastasectomy for gastrointestinal stromal tumors. *Journal of Surgical Oncology*, *109*(1), 23–27. <https://doi.org/10.1002/jso.23451>
- Blay, J. Y. (2010). A decade of tyrosine kinase inhibitor therapy: Historical and current perspectives on targeted therapy for GIST. *Cancer Treatment Reviews*, *37*(5), 373–384. <https://doi.org/10.1016/j.ctrv.2010.11.003>
- Heinrich, M. C., Maki, R. G., Corless, C. L., Antonescu, C. R., Harlow, A., Griffith, D.,...Demetri, G. D. (2008). Primary and secondary kinase genotypes correlate with the biological and clinical activity of sunitinib in imatinib-resistant gastrointestinal stromal tumor. *Journal of Clinical Oncology*, *26*(33), 5352–5359. <https://doi.org/10.1200/JCO.2007.15.7461>
- Huang, W. K., Wu, C. E., Wang, S. Y., Chang, C. F., Chou, W. C., Chen, J. S., & Yeh, C. N. (2022). Systemic therapy for gastrointestinal stromal tumor: Current standards and emerging challenges. *Current Treatment Options in Oncology*, *23*(9), 1303–1319. <https://doi.org/10.1007/s11864-022-00996-8>
- Joensuu, H., Hohenberger, P., & Corless, C. L. (2013). Gastrointestinal stromal tumor. *Lancet*, *382*, 973–983. [https://doi.org/10.1016/S0140-6736\(13\)60106-3](https://doi.org/10.1016/S0140-6736(13)60106-3)
- Kelly, C. M., Gutierrez Sainz, L., & Chi, P. (2021). The management of metastatic GIST: Current standard and investigational therapeutics. *Journal of Hematology & Oncology*, *14*(1), 2. <https://doi.org/10.1186/s13045-020-01026-6>
- Lim, K. T., & Tan, K. Y. (2017). Current research and treatment for gastrointestinal stromal tumors. *World Journal of Gastroenterology*, *23*(27), 4856–4866. <https://doi.org/10.3748/wjg.v23.i27.4856>
- Lorincz, A., Redelman, D., Horvath, V. J., Bardsley, M. R., Chen, H., & Ordog, T. (2008). Progenitors of interstitial cells of Cajal in the postnatal murine stomach. *Gastroenterology*, *134*, 1083–1093.
- Nishida, T., Hølmekjær, T., Raut, C. P., & Rutkowski, P. (2019). Defining tumor rupture in gastrointestinal stromal tumor. *Annals of Surgical Oncology*, *26*(6), 1669–1675. <https://doi.org/10.1245/s10434-019-07297-9>
- Patel, R., Clancy, R., Crowther, E., Vannahme, M., & Pullyblank, A. (2013). A rectal bleeding algorithm can successfully reduce emergency admissions. *Colorectal Disease*, *16*, 377–381. <https://doi.org/10.1111/codi.12524>
- Søreide, K., Sandvik, O. M., Søreide, J. A., Giljaca, V., Jurckova, A., & Bulusu, V. R. (2016). Global epidemiology of gastrointestinal stromal tumours (GIST): A systematic review of population-based cohort studies. *Cancer Epidemiology*, *40*, 39–46. <https://doi.org/10.1016/j.canep.2015.10.031>
- van Roggen, G., Hogendoorn, P. C., & van Velthuysen, M. L. (2001). The histopathological differential diagnosis of gastrointestinal stromal tumours. *Journal of Clinical Pathology*, *54*(2), 96–102. <https://doi.org/10.1136/jcp.54.2.96>
- Vernuccio, F., Taibbi, A., Picone, D., LA Grutta, L., Midiri, M., Lagalla, R., Lo Re, G., & Bartolotta, T. V. (2016). Imaging of gastrointestinal stromal tumors: From diagnosis to evaluation of therapeutic response. *Anticancer Research*, *36*(6), 2639–2648.
- von Mehren, M., & Joensuu, H. (2018). Gastrointestinal stromal tumors. *Journal of Clinical Oncology*, *36*(2), 136–143. <https://doi.org/10.1200/jco.2017.74.9705>