

Diagnostic Snapshot



Mysterious Arm Swelling in a Patient With Non-Hodgkin Lymphoma Complicated by Superior Vena Cava Syndrome

JESSICA S. JANG, RN, MSN, ACNP-BC, and JEFFREY S. JANG, BS

From ¹Stanford Health Care, Palo Alto, California; ²The George Washington University School of Medicine and Health Sciences, Washington, DC

Authors' disclosures of conflicts of interest are found at the end of this article.

Correspondence to Jessica S. Jang, RN, MSN, ACNP-BC, 300 Pasteur Drive, Stanford, CA 94305. E-mail: jess.jang@gmail.com

<https://doi.org/10.6004/jadpro.2022.13.1.8>

© 2022 Harborside™

Abstract

Hematologic malignancies often create difficult venous complications. Specifically, with lymphoma, the risk of venous thromboembolism (VTE) is high, often requiring highly specialized accuracy in balancing this coagulopathy. This case study demonstrates a situation where the advanced practitioner participated in the differential diagnosis of VTEs, management, and workup of subsequent central venous complications in a patient with non-Hodgkin lymphoma and superior vena cava syndrome.

HISTORY

OJ is a 40-year-old female with no significant past medical history. In January 2021, she noticed that her left neck veins were bulging, and she was diagnosed with a left internal jugular deep vein thrombosis. She was placed on apixaban and subsequently rivaroxaban and had a workup for thrombophilia, including factor V Leiden, prothrombin mutation, antithrombin III activity, protein C activity, lupus anticoagulant, and anticardiolipin, all of which were unremarkable.

At this time, her thrombus was deemed unprovoked. As OJ is a professional dancer, her clinician considered the thrombus to perhaps be attributed to her chronic left-sided muscle spasms, which have become worse recently. After 3 months of compliant rivaroxaban therapy, OJ experienced significant sinusitis with discharge, pain, cough, and wheezing. She was prescribed amoxicillin clavulanate and prednisone for 2 weeks, and her symptoms

improved instantly after starting the prednisone. Two weeks later, she received her first COVID-19 vaccine, and subsequently developed rapid and severe respiratory symptoms with dyspnea, cough, wheezing, chills, aches, and worsening left-sided muscle spasms that led her to seek treatment in the emergency department on April 13, 2021, where she was admitted for hospitalization.

In the hospital, her workup led to obtaining a PET/CT. The scan found a large hypermetabolic anterior mediastinal mass with significant compression of heart and adjacent mediastinal structures causing narrowing on the left main bronchus with lymphomatous spread to pericardiophrenic and abdominal nodes. She was diagnosed with superior vena cava (SVC) syndrome. An anterior mediastinoscopy was done, and a biopsy diagnosed primary mediastinal large B-cell lymphoma. Thoracic surgery did not recommend surgical intervention, and systemic treatment to target the lym-

phoma mass was immediately pursued on April 20 with inpatient chemotherapy dose-adjusted rituximab, etoposide, prednisone, vincristine sulfate, cyclophosphamide, and doxorubicin hydrochloride (DA-R-EPOCH).

Unfortunately, immediately after her first chemotherapy cycle, OJ was diagnosed with an acute peripherally inserted central catheter (PICC)-associated right occlusive superficial thrombus in the proximal subclavian vein full occlusion of the left brachiocephalic vein. Since she had already developed clots while taking prior direct oral anti-

coagulant (DOAC) agents (first apixaban, then rivaroxaban), her oncologist switched to therapeutic weight-based enoxaparin injections. To complicate things further, OJ experienced a nadir (dropping to undetectable absolute neutrophil count levels) following her first cycle of chemotherapy making her clinical picture quite fragile, as she remained at high risk for simultaneously bleeding and clotting if the dose of her anticoagulation was not precise. She was discharged from the hospital after completing cycle 1 DA-R-EPOCH with plans to return for subsequent five cycles during planned hospital admissions.

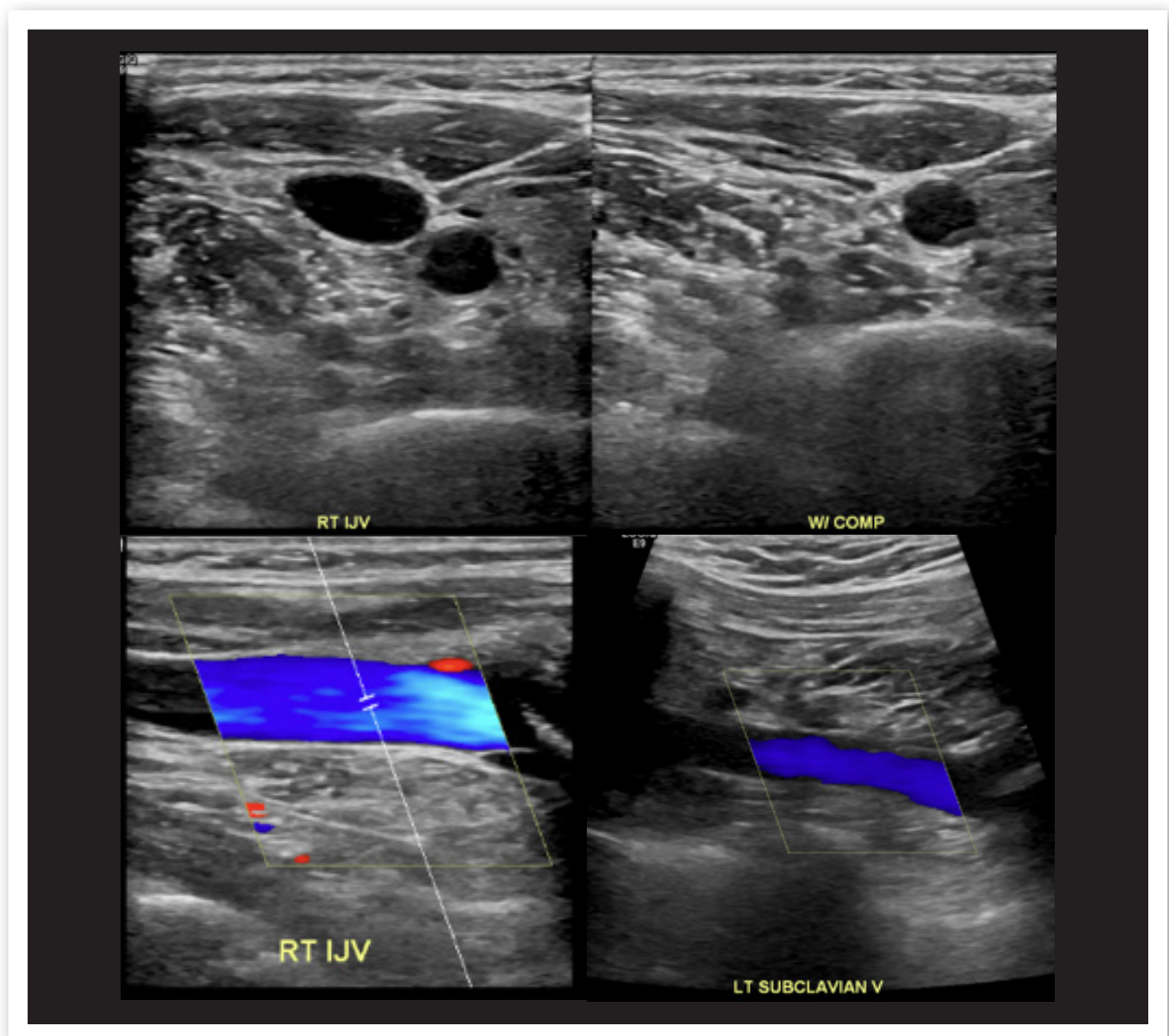


Figure 1. Images from the ultrasound of the right upper extremity.

PRESENTATION

Prior to OJ's cycle 3 of DA-R-EPOCH, a port was placed outpatient for central access and chemotherapy admission. The procedure was uneventful with no complications. She was admitted to the hospital for the planned chemotherapy. She denied any missed or skipped doses of enoxaparin. On June 6, 2021, during her cycle 3, OJ experienced chest palpitations, acute right upper arm swelling, tachycardia, right arm pain, and tenderness. She described her pain as "angry," although unclear if sharp or aching. She was unable to determine if her pain was "burning" vs. "stabbing" or "aching." She also reported chest palpitations that were exacerbated when she ambulated or did any physical exertion. She reported high levels of anxiety and stress. She denied shortness of breath or difficulty breathing at rest or on exertion. She denied chest pain. She denied leg swelling or calf tenderness. She denied infectious symptoms.

OJ appeared very anxious and because her port site was painful she requested the needle to be exchanged. During the port needle exchange she became fearful, tearful, upset, and required oral benzodiazepines and low-dose opiates to aid her. Her port was oozing from the site, with significant tenderness and hematoma to the area causing extreme pain. Her right arm was swollen, visibly larger compared with the left arm. She had present peripheral pulses. There was no evidence of erythema, rashes, lesions. Aside from the palpable port in the right upper chest, there were no masses or nodules. Her arm was soft with no pitting edema. It was neither firm nor taught. She had a heart rate of 65 to 112 at rest, a respiratory rate of 18 to 20, O₂ saturation over 99% on room air, systolic blood pressure of 119 to 126, and diastolic 64 to 74.

WORKUP

A repeat complete blood count demonstrated a hemoglobin of 9.3, hematocrit 29.7, and an anti-Xa level of 0.89. On June 6, 2021, she had an ultrasound of the right upper extremity that showed no evidence of a deep vein thrombosis. A CT chest venogram on June 1 immediately prior to the admission showed decreased size of an anterior mass that encased the left brachiocephalic vein and protruded into the upper SVC, with decreased luminal narrowing. There was a persistent partially occlusive thrombus in the right subclavian vein and nonocclusive, eccentric thrombus in the caudal aspect of the left internal jugular vein. Remaining veins were patent without thrombus or significant stenosis (Figure 1).

DISCUSSION

The ultrasound was negative for new thrombus. The medical team did not elect to repeat a CT because OJ had a recent CT chest venogram study on a prior admission. Also, her anti-Xa level showed that she was in the range of being therapeutically anticoagulated. OJ was not hypoxic; however, she was tachycardic, tachypneic, and reported chest palpitations, all concerning for VTE. OJ's symptoms were concerning because there were certainly some common signs and symptoms of an acute thrombus. The indication was concerning because she had already failed two prior anticoagulants (apixaban and rivaroxaban) and was on her third line. A new thrombus would suggest that either she was subtherapeutic on enoxaparin or the anticoagulant itself was ineffective. However, her workup thus far was negative for an acute thrombus, forcing her medical team to question the true nature of her arm swelling and associated symptoms.



WHAT IS THE CORRECT DIAGNOSIS?

A

Venous thromboembolism (VTE) of the right upper extremity

B

Superior vena cava (SVC) syndrome

C

Central venous port-associated phlebitis



WHAT IS THE CORRECT DIAGNOSIS?

- A Venous thromboembolism (VTE) of the right upper extremity
- B Superior vena cava (SVC) syndrome
- C Central venous port–associated phlebitis (correct answer)

A VTE of the right upper extremity. We know that patients with malignancies are at higher risk for developing thrombosis due to hypercoagulable state. The risk of venous thromboembolism (VTE) varies depending on the malignancy. Pancreatic and gastric malignancies can be considered very high risk. Lymphomas can fall into the category of high risk for VTE. Furthermore, patients with malignancies who have suffered a VTE are at higher risk for recurrence than patients without cancer who had a VTE (Mahajan et al., 2019). In the case of lymphoma, thrombosis can be the result of treatment or the malignancy itself. A VTE can indicate an occult metastasis, and recurrent idiopathic thrombosis warrants further investigation for malignancy (Caruso et al., 2010).

Since OJ's thrombus progressed through oral anticoagulation, she was switched to enoxaparin injections, allowing clinicians to monitor her serum levels for therapeutic accuracy. Enoxaparin efficacy for treating VTE is widely recognized. Standard of care therapeutic dosing is 1 mg/kg injected subcutaneously twice daily (Key et al., 2020). OJ weighed approximately 80 kg, making her therapeutic dose 80 mg twice daily. However, given her aforementioned clinical fragility, her oncologist decided to place her on a slightly decreased dose of 60 mg twice daily and shortly after initiation drew an anti-factor Xa level, which was 0.83 on April 19. The therapeutic range used at this institution is 0.5 to 1.0. OJ's repeat anti-factor Xa level was 0.89 on June 6, suggesting she was in fact therapeutically anticoagulated.

Monitoring anti-factor Xa levels is a more patient-specific method of achieving optimal anticoagulation as opposed to weight-based dosing at 1 mg/kg twice daily. It has been utilized over weight-based dosing in certain instances, such as obese, pregnant, and renally impaired patients. No defined standard exists for a therapeutic reference range for monitoring anti-factor Xa levels; however, literature points to a reasonable reference range between 0.2 to 0.5 IU/mL (Wei & Ward,

2015). The utility of measuring anti-factor Xa levels is still being studied. In a study of surgical oncology patients, it has been shown that patients on weight-based dosing may receive subprophylactic levels of enoxaparin. Monitoring anti-factor Xa levels to stay within therapeutic range decreased incidences of VTE without any increase in major bleeding in that cohort (Kramme et al., 2020). In nonsurgical patients, there is a paucity of evidence to support anti-factor Xa–guided dosing. Evidence suggests that in cancer patients with a subsequent VTE, weight-based dosing had no significant difference in recurrent VTE or major bleed when compared with anti-factor Xa level dosing (Hart et al., 2021). There is still a need to further study the use of anti-factor Xa–directed therapy in nonsurgical oncology patients, specifically those with hematologic malignancies. In regards to OJ, there is no reason to suggest that she was at any higher risk of VTE due to the management of her prophylactic anticoagulation.

In addition to serum anti-factor Xa levels, a repeat right upper extremity ultrasound confirmed the absence of new right upper extremity thrombosis, and in fact showed improvement in prior clot burden, therefore not supporting VTE as the diagnosis.

B SVC syndrome. Superior vena cava syndrome is a collection of symptoms and signs caused by the obstruction of the SVC as a result of a thrombus or tumor infiltration in the vessel wall. Common history and physical exam findings include face and neck swelling, upper extremity swelling, distended neck veins, cough, dyspnea, orthopnea, distended chest vein collaterals, and conjunctival suffusion. It is most commonly seen secondary to malignancy, and non-Hodgkin lymphoma is the second most common malignancy associated with SVC syndrome (Steligson & Surowiec, 2020). Superior vena cava syndrome is a clinical diagnosis, but can be confirmed via imaging, including contrast CT. Management includes steroids, radia-

tion, chemotherapy to reduce tumor size, and intravascular stenting (Higdon et al., 2018).

In a retrospective study that evaluated the signs and symptoms of SVC syndrome, 68% of patients presented with upper extremity swelling. The presence of a central catheter also increases the risk of VTE and subsequent SVC syndrome (Rice et al., 2006). OJ certainly did experience signs and symptoms of SVC syndrome early in her history when she was actually diagnosed with it; however, this time, she lacked the majority of presenting symptoms to support recurrent SVC syndrome. Furthermore, her repeat CT showed significant improvement in mediastinal tumor involvement making clinical suspicion for recurrent SVC syndrome unlikely.

C Central venous port-associated phlebitis (correct answer). Phlebitis is defined as inflammation or irritation of the vein (Macklin, 2003). Most literature accounts the prevalence of phlebitis in peripheral lines; however, there is some evidence of occurrence in central lines as well (Cohen, 2012; Luckianow et al., 2016). In this case, mechanical phlebitis was from irritation of the venous endothelium surrounding the port site where signs and symptoms included tenderness, erythema, and edema.

OJ also experienced significant bruising and oozing from her port site with a visible firm hematoma surrounding the area. Minor hematomas in the chest wall in the area of port implantation occur in up to 8% and usually regress completely without further treatment (Machat et al., 2019). OJ had requested the site to be de-accessed and re-accessed in the second needle hole for comfort. This may or may not have contributed to worsening inflammation. There was a study that looked at how palpating the PICC site in neonates causes phlebitis and early removal of line. While this study was done on neonates rather than adults, it supports the notion that frequent physical palpation can lead to increased pain and discomfort in central line placement (Igarashi et al., 2021). Anxiety, while not known to increase risk factors, is also commonly associated with central lines. A randomized trial found that central venous lines are a huge source of anxiety in cancer patients (Yayla & Odezmir, 2019).

The treatment for phlebitis includes heat application (such as a warm compress) and nonsteroidal anti-inflammatory drugs until symptoms subside, generally within 72 hours of onset. OJ's symptoms dramatically improved with these supportive measures and were nearly resolved by the time she was discharged from the hospital. Although OJ did not have diagnostic imaging to support phlebitis, diagnosis of exclusion and resolution of arm swelling with supportive care made central line phlebitis the most appropriate diagnosis in this case.

CONCLUSION

While the correct answer ended up being the most benign, it is important to consider the differentials given the complicated nature of this case. The risk of a serious complication such as VTE was certainly high. A thorough and thoughtful analysis of the patient's presentation and workup results was prudent given that another acute VTE would have serious implications and complications, especially in a delicately anticoagulated patient. It was important for us to analyze her anticoagulation and feel confident in the enoxaparin treatment plan moving forward. Also, understanding and recognizing central line phlebitis is important. It can oftentimes lead clinicians to worry about more serious complications, subjecting the patient to overtesting or fear. Recognizing phlebitis early and implementing noninvasive supportive measures are often effective in ameliorating both physical symptoms and psychosocial symptoms of cancer patients. ●

Disclosure

The authors have no conflicts of interest to disclose.

References

- Caruso, V., Di Castelnuovo, A., Meschengieser, S., Lazzari, M. A., de Gaetano, G., Storti, S.,...Donati, M. B. (2010). Thrombotic complications in adult patients with lymphoma: A meta-analysis of 29 independent cohorts including 18 018 patients and 1149 events. *Blood*, *115*(26), 5322–5328. <https://doi.org/10.1182/blood-2010-01-258624>
- Cohen, M. J. (2012). Towards hemostatic resuscitation. *Surgical Clinics of North America*, *92*(4), 877–891. <https://doi.org/10.1016/j.suc.2012.06.001>
- Hart, K., Andrick, B., Grassi, S., Manikowski, J., & Graham, J. (2021). Cancer-associated venous thromboembolism

- treatment with anti-Xa versus weight-based enoxaparin: A retrospective evaluation of safety and efficacy. *Annals of Pharmacotherapy*, 55(9), 1120–1126. <https://doi.org/10.1177/1060028020988362>
- Higdon, M. L., Atkinson, C. J., & Lawrence, K. V. (2018). Oncologic emergencies: Recognition and initial management. *American Family Physician*, 97(11), 741–748. <https://www.aafp.org/afp/2018/0601/p741.html>
- Igarashi, A., Okuno, T., Shimizu, T., Ohta, G., & Ohshima, Y. (2021). Mechanical stimulation is a risk factor for phlebitis associated with peripherally inserted central venous catheter in neonates. *Pediatrics International*, 63(5), 561–564. <https://doi.org/10.1111/ped.14476>
- Key, N. S., Khorana, A. A., Kuderer, N. M., Bohlke, K., Lee, A. Y. Y., Arcelus, J. I.,...Falanga, A. (2020). Venous thromboembolism prophylaxis and treatment in patients with cancer: ASCO Clinical Practice Guideline Update. *Journal of Clinical Oncology*, 38(5), 496–520. <https://doi.org/10.1200/jco.19.01461>
- Kramme, K., Sarraf, P., & Munene, G. (2020). Prophylactic enoxaparin adjusted by anti-factor Xa peak levels compared with recommended thromboprophylaxis and rates of clinically evident venous thromboembolism in surgical oncology patients. *Journal of the American College of Surgeons*, 230(3), 314–321. <https://doi.org/10.1016/j.jamcollsurg.2019.11.012>
- Luckianow, G. M., Smith, D., Bullen, D., & Kaplan, L. J. (2016). Understanding percutaneous and subcutaneous central venous access devices. *Journal of the American Academy of Physician Assistants*, 29(1), 33–36. <https://doi.org/10.1097/01.jaa.0000472630.68218.42>
- Machat, S., Eisenhuber, E., Pfarl, G., Stübler, J., Koelblinger, C., Zacherl, J., & Schima, W. (2019). Complications of central venous port systems: A pictorial review. *Insights Into Imaging*, 10(1), 86. <https://doi.org/10.1186/s13244-019-0770-2>
- Macklin, D. (2003). Phlebitis. *American Journal of Nursing*, 103(2), 55–60. <https://doi.org/10.1097/00000446-200302000-00027>
- Mahajan, A., Brunson, A., White, R., & Wun, T. (2019). The epidemiology of cancer-associated venous thromboembolism: An update. *Seminars in Thrombosis and Hemostasis*, 45(4), 321–325. <https://doi.org/10.1055/s-0039-1688494>
- Rice, T. W., Rodriguez, R. M., & Light, R. W. (2006). The superior vena cava syndrome: Clinical characteristics and evolving etiology. *Medicine*, 85(1), 37–42. <https://doi.org/10.1097/01.md.0000198474.99876.f0>
- Seligson, M. T., & Surowiec, S. M. (2020). Superior vena cava syndrome. In StatPearls. StatPearls Publishing.
- Wei, M. Y., & Ward, S. M. (2015). The anti-factor Xa range for low molecular weight heparin thromboprophylaxis. *Hematology Reports*, 7(4), 5844. <https://doi.org/10.4081/hr.2015.5844>
- Yayla, E. M., & Ozdemir, L. (2019). Effect of inhalation aromatherapy on procedural pain and anxiety after needle insertion into an implantable central venous port catheter. *Cancer Nursing*, 42(1), 35–41. <https://doi.org/10.1097/ncc.0000000000000551>