

Diagnostic Snapshot



Persistent Fever While on Broad-Spectrum Antibiotics in a Patient With Squamous Cell Carcinoma

XIN LI, CRNP, AOCNP®

From University of Maryland Marlene and Stewart Greenebaum Comprehensive Cancer Center, Baltimore, Maryland

Author's disclosure of conflicts of interest is found at the end of this article.

Correspondence to: Xin Li, CRNP, AOCNP®, University of Maryland Marlene and Stewart Greenebaum Comprehensive Cancer Center, 22 S Greene Street, Baltimore, MD 21201. E-mail: lixin.0221@gmail.com

<https://doi.org/10.6004/jadpro.2021.12.7.9>

Abstract

For solid tumor patients, acute infectious process is often underestimated, especially when caused by fungal, viral, or other atypical pathogens. Providers should perform a comprehensive infectious workup to rule out uncommon pathogen-induced infection before considering tumor fever. Active infection can be life threatening given most patients with cancer are receiving chemotherapy, immunotherapy, or even cellular therapy, as is the case with the patient discussed in this article.

HISTORY

Mr. AK is a 47-year-old male with past medical history of alcoholism, tobacco abuse, and squamous cell carcinoma of the mandible (pT4N0M0, stage IVA, p16-) diagnosed in January 2020. He was status post hemimandibulectomy, tracheostomy, and bilateral selective neck dissection with fibular free flap reconstruction followed by adjuvant radiotherapy on May 2020. Unfortunately, his disease was found to progress on PET scan in September 2020 with new lung metastasis, for which he underwent left lower lobe wedge resection. He received one dose of pembrolizumab (Keytruda) on December 9, 2020, with a tentative plan for trial for lymphodepletion preparative chemotherapy with fludarabine and cyclophosphamide followed by infusion of tumor-infiltrating leukocytes with interleukin-2 (IL-2) infusion in January 2021.

CHIEF COMPLAINT

He was admitted to the hospital from December 15, 2020, to January 8, 2021, initially with con-

cerns of percutaneous endoscopic gastrostomy (PEG) tube infection due to localized burning and pain. Upon admission, he was afebrile; however, 24 hours after being admitted, on December 16, he was noted to have fever intermittently with the highest temperature documented as 38.8°C. This was initially thought to be secondary to cellulitis around the PEG tube. Abdominal CT did not reveal any abscess or fluid collection at the PEG site. Therefore, Mr. AK was treated with IV vancomycin (December 15 to 18) then switched to doxycycline to complete a 7-day course for soft tissue infection (treatment ended December 23). Regardless of gram-positive coverage, he had persistent fever. Therefore, he was also started on piperacillin/tazobactam on December 18.

INFECTIOUS WORKUP

Meanwhile, in order to rule out other infectious etiology that could lead to his fever, the inpatient team performed an infectious workup including blood culture and urine culture that both turned

out to be negative. CT chest and sinus was also done on December 21, which showed no signs or symptoms of sinusitis, but again a necrotic lung mass was noted to the left lower lobe increasing in size with associated ground-glass opacities. The interventional pulmonology team was consulted and reviewed the chest CT. Necrotic lung mass was suspected to be the source of his fevers rather than a respiratory infection. Based on discussion with the pulmonology team and infectious disease team, piperacillin/tazobactam was also stopped on December 23. Mr. AK was given indomethacin to treat the tumor fever.

On December 27, Mr. AK started to develop new onset of left pleuritic pain radiating to the left chest wall. Cardiac workup was negative. He was not neutropenic. Table 1 shows that the complete blood count and comprehensive metabolic panel were grossly normal.

FURTHER WORKUP

Blood cultures performed on December 26 were negative, and a urine culture performed on December 27 was negative. A chest/abdomen/pelvis CT without contrast was repeated on December 27. The abdominal CT was unremarkable, and Figures 1 and 2 show the CT comparison.

Table 1. Patient Labs

	Value	Reference
White blood cell count	7.1 K/ μ L	4.5–11.0 K/ μ L
Hemoglobin	8.9 g/dL	12.6–17.4 g/dL
Hematocrit	26.9%	37.0%–50.0%
Platelets	519 K/ μ L	153–367 K/ μ L
Absolute neutrophil count	5.00 K/ μ L	1.70–7.30 K/ μ L
Absolute lymphocyte count	0.7 K/ μ L	1.30–3.50 K/ μ L

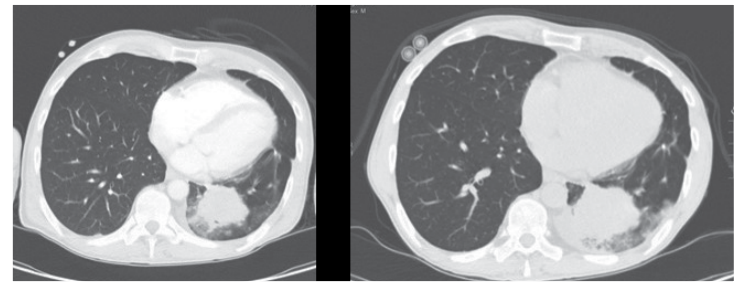


Figure 1. Largest necrotic mass to lower left lobe. Left side was done on December 21, 2020, and right side was done on December 27, 2020.

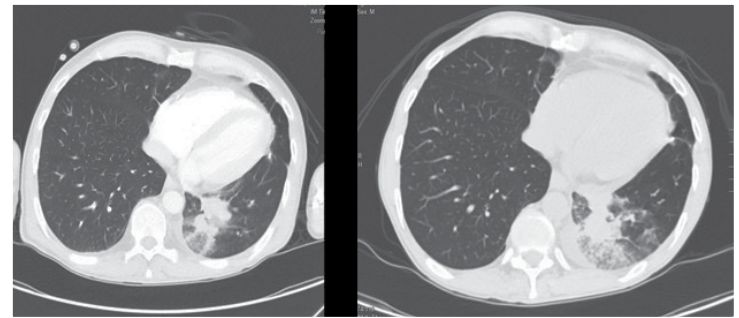


Figure 2. Associated ground-glass opacities to left lower lobe. Left side was done on December 21, 2020, and right side was done on December 27, 2020.



WHAT IS THE CORRECT DIAGNOSIS?

- A** Disease progression
- B** Explore other pathogens for infectious process other than bacteria
- C** Post-obstructive pneumonia
- D** Pneumonitis due to recent pembrolizumab infusion

WHAT IS THE CORRECT DIAGNOSIS?

- A Disease progression
- B Explore other pathogens for infectious process other than bacteria (Correct Answer)**
- C Post-obstructive pneumonia
- D Pneumonitis due to recent pembrolizumab infusion

A Disease progression. If this is the case, the clinical trial team will need to be contacted to suggest starting lymphodepleting chemotherapy as soon as possible. There is no doubt that Mr. AK's cancer is rapidly progressing. Necrotic mass was increasing in size in 2 weeks, which was confirmed on CT scan. However, in the setting of fever with new onset of pleuritic pain, a patient can face a high risk of infectious complications/reactivations if treated with further lymphodepletion chemotherapy as preparative treatment for a tumor-infiltrating leukocytes trial. Hence, the clinical trial was on hold pending adequate treatment course for active fungal pneumonia. Mr. AK was started on radiation for progressive disease, which was a safer way to control his cancer.

B Explore other pathogens for infectious process other than bacteria; interventional pulmonology should be reinvented in care since a bronchoscopy may be indicated. Mr. AK's complete blood count showed lymphopenia in the setting of persistent fever, which did not resolve with broad-coverage IV antibiotics. Other infectious etiology including fungal infection needs to be taken into consideration. In Mr. AK's case, bronchoscopy with bronchoalveolar lavage (BAL) was performed by the pulmonology team on December 30, 2020, and *Aspergillus* antigen was positive in BAL culture. He was started on voriconazole. His pleuritic pain significantly improved 72 hours after starting antifungal treatment with improved fever curve. Upon discharge, he remained afebrile for over 48 hours.

C Post-obstructive pneumonia, which would need to be treated with antibiotics. Mr. AK was treated with a 7-day course of piperacillin/tazobactam, as mentioned previously, which should sufficiently cover obstructive pneumonia if this had been the cause of his fever. However, he did not improve with IV broad-spectrum antibiotics, which made this option unlikely.

D Pneumonitis due to recent pembrolizumab infusion. Mr. AK's chest CT finding is not correlated with drug-induced pneumonitis. The radiology findings in antineoplastic agent-induced pneumonitis were diffuse or multifocal ground-glass opacities commonly seen with intra-lobular interstitial thickening (Akira et al., 2002). In addition, he received only one dose of pembrolizumab. Pneumonitis onset is widely variable, reported from 9 days to more than 19 months after initiation of therapy, with a median time of onset of 2.8 months (Delaunay et al., 2017). ●

Disclosure

The author has no conflicts of interest to disclose.

Reference

- Akira, M., Ishikawa, H., & Yamamoto, S. (2002). Drug-induced pneumonitis: Thin-section CT findings in 60 patients. *Radiology*, 224(3), 852–860. <https://doi.org/10.1148/radiol.2243011236>
- Delaunay, M., Cadranet, J., Lusque, A., Meyer, N., Gounaut, V., Moro-Sibilot, D.,...Audigier-Valette, C. (2017). Immune-checkpoint inhibitors associated with interstitial lung disease in cancer patients. *European Respiratory Journal*, 50(2), 1700050. <https://doi.org/10.1183/13993003.00050-2017>